


SYSTEMATIC REVIEW AND META-ANALYSIS

Extracorporeal Life Support in Pregnancy: A Systematic Review

Emily E. Naoum , MD; Andrew Chalupka, MD, MBA; Jonathan Haft, MD; Mark MacEachern, MLIS; Cosmas J. M. Vandeven, MD; Sarah Rae Easter, MD; Michael Maile, MD, MS; Brian T. Bateman, MD, MSc; Melissa E. Bauer, DO

BACKGROUND: The use of extracorporeal life support (ECLS) has expanded to include unique populations such as peripartum women. This systematic review aims to (1) quantify the number of cases and indications for ECLS in women during the peripartum period reported in the literature and (2) report maternal and fetal complications and outcomes associated with peripartum ECLS.

METHODS AND RESULTS: This review was registered in PROSPERO (CRD42018108142). MEDLINE, Embase, and CINAHL were searched for case reports, case series, and studies reporting cases of ECLS during the peripartum period that reported one or more of the following outcomes: maternal survival, maternal complications, fetal survival, and/or fetal complications. Qualitative assessment of 221 publications evaluated the number of cases, clinical details, and maternal and fetal outcomes of ECLS during the peripartum period. There were 358 women included and 68 reported fetal outcomes in cases where the mother was pregnant at the time of cannulation. The aggregate maternal survival at 30 days was 270 (75.4%) and at 1 year was 266 (74.3%); fetal survival was 44 (64.7%). The most common indications for ECLS overall in pregnancy included acute respiratory distress syndrome 177 (49.4%), cardiac failure 67 (18.7%), and cardiac arrest 57 (15.9%). The most common maternal complications included mild to moderate bleeding 66 (18.4%), severe bleeding requiring surgical intervention 48 (13.4%), and intracranial neurologic morbidity 19 (5.3%). The most commonly reported fetal complications included preterm delivery 33 (48.5%) and neonatal intensive care unit admission 19 (27.9%).

CONCLUSIONS: Reported rates of survival in ECLS in pregnant and postpartum women are high and major complications relatively low.

Key Words: extracorporeal circulation ■ extracorporeal membrane oxygenation ■ pregnancy and postpartum

Cardiovascular disease is currently the leading cause of pregnancy-related mortality in the United States, contributing to more than a quarter (26%) of maternal deaths and as well as severe maternal morbidity.^{1,2} Pregnant women are becoming more medically complex with chronic health conditions that may predispose them to cardiopulmonary complications during pregnancy.^{3–6} Given the rise in conditions for which extracorporeal life support (ECLS) including extracorporeal membrane oxygenation (ECMO) may be indicated, providers must understand the uses and limitations of advanced medical therapies such

as ECLS. The relative rarity of catastrophic cardiopulmonary disease in the peripartum period requiring ECLS makes it difficult to study. Existing systematic reviews are narrow in scope (for example, evaluating only certain causative conditions such as acute respiratory distress syndrome [ARDS]) and small in size (the largest studies report <70 patients).^{7–10} Combining past studies for all conditions in a systematic review will enhance the understanding of how to identify patients who will benefit from ECLS, develop appropriate use, and provide data to counsel patients and their families. The aim of this systematic review is to perform a

Correspondence to: Emily E. Naoum, MD, 1500 E Medical Center Dr, Ann Arbor, MI 48109. E-mail: eminaoum@umich.edu

Supplementary Materials for this article are available at <https://www.ahajournals.org/doi/suppl/10.1161/JAHA.119.016072>

For Sources of Funding and Disclosures, see page 9.

© 2020 The Authors. Published on behalf of the American Heart Association, Inc., by Wiley. This is an open access article under the terms of the Creative Commons Attribution-NonCommercial-NoDerivs License, which permits use and distribution in any medium, provided the original work is properly cited, the use is non-commercial and no modifications or adaptations are made.

JAHA is available at: www.ahajournals.org/journal/jaha

CLINICAL PERSPECTIVE

What Is New?

- With the increasing medical complexity of women of childbearing age, the potential for catastrophic complications of pregnancy may call for advanced therapies including extracorporeal life support.

What Are the Clinical Implications?

- Venovenous and venoarterial extracorporeal support may be implemented for a variety of severe cardiopulmonary conditions in pregnant patients with reasonable success and safety for mother and fetus.

Nonstandard Abbreviations and Acronyms

ARDS	acute respiratory distress syndrome
ECLS	extracorporeal life support
ECMO	extracorporeal membrane oxygenation

comprehensive search of ECLS in the pregnant and postpartum periods, to define the reported indications as well as maternal and fetal survival, and to identify associated complications.

METHODS

This systematic review was registered in PROSPERO (CRD42018108142) and the Preferred Reporting Items for Systematic Reviews and Meta-Analyses (PRISMA) guidelines were reviewed and maintained when performing this systematic review.¹¹ This study was exempt from institutional review board approval as a systematic review of published literature. The authors declare that all supporting data are available within the article and its online supplementary files.

Literature Search

A comprehensive literature search was performed on September 11, 2018 for this systematic review using OVID MEDLINE (1946-), Elsevier Embase (1947-), and EBSCOhost CINAHL (1937-) databases from time of inception to capture studies regarding ECLS in the pregnant and postpartum periods with no limit placed on language or date of publication, but studies that describe the use of ECMO in children were excluded. A selection of sentinel articles was used to

generate search terms and test retrieval in all of the databases. The complete searches can be found in Data S1.

Study Selection

After the search was completed, 2 authors (E.E.N., A.N.C.) reviewed each abstract independently for consideration of full text review. The same 2 authors independently reviewed the full text articles for inclusion in the systematic review. A search using the Web of Science from February 28 through March 1, 2019 identified the articles in the bibliographies as well as citations of the selected articles and were also screened for inclusion. An additional study was found through preexisting subject knowledge and included. Once final articles were selected, data were extracted by one author (E.E.N.) and validated by another (A.N.C.). Google Translate was used for non-English texts and information was collected from adequately translated articles for those that met inclusion criteria. Any discrepancies were resolved by discussion. Figure 1 depicts a flowchart of study selection.

Case reports, case series, meeting abstracts, correspondences, and any other type of study that reported one or more of the following were included: maternal survival, fetal survival, maternal complications, and/or fetal complications with the use of ECLS during pregnancy or within the postpartum period (the first 42 days after delivery). Studies in which the patients did not clearly undergo ECLS, underwent cardiopulmonary bypass for cardiac surgery only, or underwent immediate cardiac mechanical support (eg, left ventricular assist device, biventricular assist device) were excluded. Cases in which initiation of extracorporeal support was unclear were reviewed by 2 authors (E.E.N., M.E.B.) for inclusion and those where initiation was more than 42 days postpartum were excluded.

The following criteria were used for exclusion of studies: patients who were not pregnant or more than 42 days postpartum, studies not reporting either maternal or fetal outcomes, nonhuman studies, non-English studies without adequate translation, editorials, narrative review articles, and systematic review articles. Articles that were excluded after full text review were recorded with reasons for exclusion. If more than one reason for exclusion was identified, articles were excluded based on the following hierarchical order: nonhuman experiment or unrelated to ECLS; unable to obtain full text or full English translation; review article or systematic review; commentary/editorials without original results; ECLS not performed; patient not pregnant; no ECLS outcomes reported; unable to differentiate outcomes from nonpregnant patients; patient >42 days postpartum; duplicate studies or overlapping cohorts.

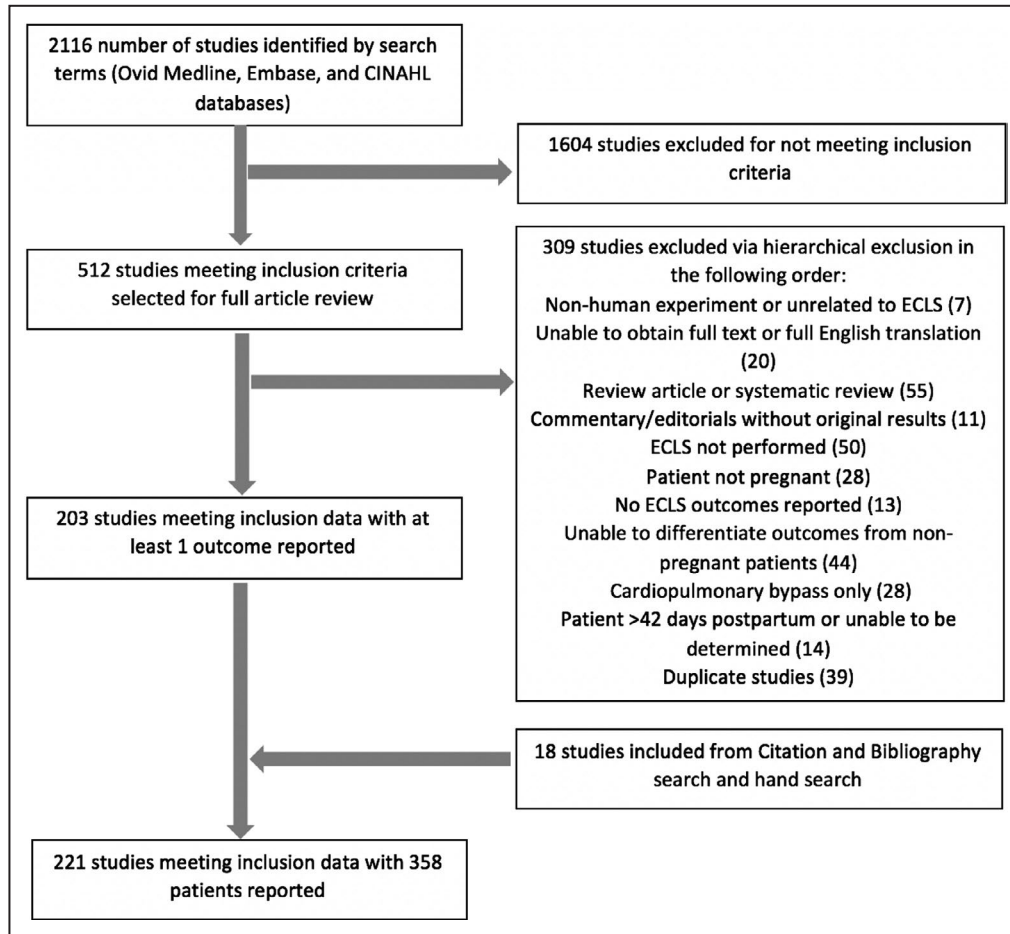


Figure 1. Flowsheet for study inclusion/exclusion.
Flow diagram of search results and study selection.

Interpretation of Data

Data were collected for indication; maternal demographics; gestational age; timing, duration, and type of ECLS; and maternal and fetal morbidity and mortality. Maternal information collected included age, gravidity/parity, disease process, ECLS duration, complications, and mortality. Obstetrical information was collected for gestational age and delivery type. Fetal information was collected for gestational age at delivery, preterm delivery, neonatal intensive care unit admission, complications, and mortality. ECLS information was collected for support type (venoarterial, venovenous, or both [venoarterial+venovenous]), duration, and indication. For cohort studies, the mean age, gravidity and parity, gestational age, and duration on ECLS were recorded. One author collected the data (E.E.N.) and the second author (A.N.C.) reviewed each study and confirmed the data. Discrepancies in the data were resolved by discussion, and if still unresolved, a third author (M.E.B.) reviewed for resolution. Authors of published articles with incomplete information were contacted by e-mail and/or telephone for further information.

Gravidity and parity was defined as described in reports on hospital admission. Vaginal deliveries included spontaneous vaginal deliveries and operative vaginal deliveries. Deliveries prior to 37 weeks were considered preterm deliveries. Any delivery prior to 32 weeks was considered to have been admitted to the neonatal intensive care unit whether or not it was explicitly stated, in accordance with the American Academy of Pediatrics guidelines on levels of neonatal care.¹²

Fetal outcomes were reported for patients who underwent ECLS while pregnant; fetal outcomes from patients who underwent ECLS immediately postpartum, postpartum, or unknown timing relative to delivery were not included. Ectopic pregnancies were not counted toward fetal mortality. Maternal cases <24 weeks with a fetal loss were reported as a spontaneous abortion and were not included in the preterm delivery count. Spontaneous abortions that occurred prior to ECLS were not included in fetal mortality. Therapeutic abortions were included in fetal mortality if the termination occurred on ECLS for maternal indications or if abortion was performed because of catastrophic fetal injury

incurred due to ECLS. Fetal survival was reported within the outcome only if it was explicitly stated in the study.

Patients were classified as being antepartum, immediately postpartum, or postpartum. Antepartum patients were those cannulated and initiated on ECLS prior to delivery. Immediately postpartum cases were identified as those patients who were cannulated and initiated on ECLS within 24 hours of delivery. Postpartum cases included patients who were cannulated and initiated on ECLS >24 hours after delivery but within 42 days of parturition. Cases that were identified as postpartum but did not have a clear time frame of <24 hours of delivery were included in the postpartum category. Indications for ECLS were noted based on case reports; some patients had multiple indications for ECLS. Patients with underlying ischemic, structural, or valvular heart disease were defined as having heart disease as well as cardiac failure as the indication for ECLS.

Mechanical support was identified as venoarterial, venovenous, or both as described in the study. Extracorporeal carbon dioxide removal, extracorporeal arteriovenous carbon dioxide removal, interventional lung assist membrane, and percutaneous extracorporeal lung assist supports were included with venovenous therapies. Cases in which the patient underwent cardiopulmonary bypass and had been previously initiated on ECLS or underwent post-cardiopulmonary bypass ECLS were included. Duration of ECLS was reported for all patients regardless of survival. Survival was reported within 30 days of discontinuation of ECLS therapy as the aim of this study is to evaluate the rescue

survivability of ECLS; additional deaths within 1 year were also reported separately. Complications included mild to moderate bleeding (qualitatively described as mild to moderate and/or the need for transfusion without invasive intervention), severe bleeding (requiring surgical or endoscopic interventions), vascular complications (limb ischemia, pseudoaneurysm, wound infection), intracranial morbidity (hypoxic brain injury, intracranial hemorrhage, hemiplegia, cerebral infarct), deep vein thrombosis, and other neurologic morbidity (peripheral neuropathy, cognitive dysfunction, need for rehabilitation after discharge, myoclonic epilepsy, amnesic disorder). Some patients had multiple complications.

Quality Assessment

Because of the low level of evidence and high risk of bias, case reports and case series were not assessed for the level of quality. Given the limited information presented, meeting abstracts and correspondence were also not assessed for level of quality.

RESULTS

Overall, 2116 studies were identified and reviewed and 221 studies met inclusion criteria. Table S1 contains the complete list of articles included and description of the studies and patients. These papers were published between 1974 and 2019. Figure 2 depicts the increasing rate of reporting of cases. Table 1 reports

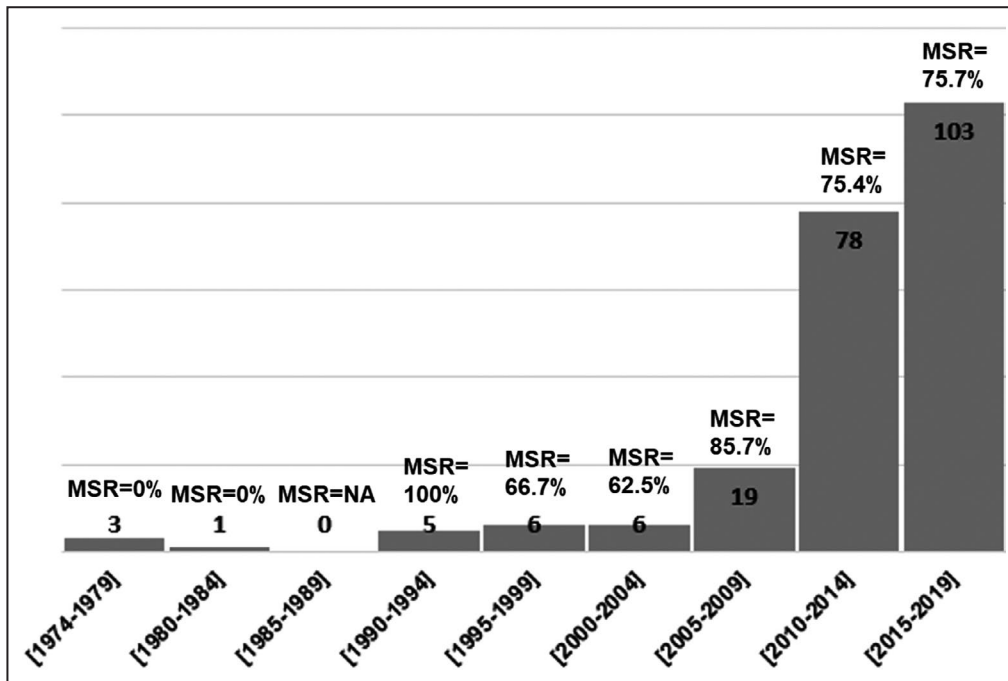


Figure 2. Case reports by year of publication. Results of the case reports by year of publication. MSR indicates the maternal survival rate for each time period described.

Table 1. Patient Characteristics

	Total Patients, n (%)
Maternal count	358 (100)
Antepartum cases with fetal outcome	68 (84.0)
Average maternal age, y (SD)	29.5 (6.1)
Median gravity/parity (range)	2/1 (G1P0–G9P8)
Median gestational age (SD)	24 wk (6.2)
Interquartile range	6.14 wk
Stage of pregnancy, n (%)	
Antepartum	81 (22.6)
Immediate postpartum	69 (19.3)
Postpartum	126 (35.2)
Uncategorized	82 (22.9)
Delivery type, n (%)	
Vaginal	67 (18.7)
Cesarean	158 (44.1)
Dilation and extraction	5 (1.4)
Not reported	128 (35.8)
Deliveries on extracorporeal membrane oxygenation, n (%)	35 (9.8)
Extracorporeal life support indications, n (%)*	
Acute respiratory distress syndrome	177 (49.4)
Cardiac failure	67 (18.7)
Cardiac arrest	57 (15.9)
Peripartum cardiomyopathy	45 (12.6)
Pulmonary arterial hypertension	28 (7.8)
Amniotic fluid embolism	27 (7.5)
Pulmonary embolism	17 (4.7)
Heart disease	14 (3.9)
Septic shock	11 (3.1)
Asthma	7 (2.0)
Malignancy	7 (2.0)
Takotsubo cardiomyopathy	6 (1.7)
Pheochromocytoma	5 (1.4)
Spontaneous coronary artery dissection	3 (0.8)
Aspiration pneumonitis	2 (0.6)
Trauma	2 (0.6)
Distributive shock	1 (0.3)
Propofol infusion syndrome	1 (0.3)
Hemorrhagic shock	1 (0.3)
Diffuse alveolar hemorrhage	1 (0.3)
Pulmonary alveolar proteinosis	1 (0.3)
Interstitial lung disease	1 (0.3)
Sickle cell crisis	1 (0.3)
Aortic dissection	1 (0.3)
Transfusion related acute lung injury	1 (0.3)
Cerebral venous thrombosis	1 (0.3)
Pulmonary hemorrhage	1 (0.3)
Cystic fibrosis	1 (0.3)
Dengue fever	1 (0.3)

(Continued)

Table 1. Continued

	Total Patients, n (%)
Extracorporeal membrane oxygenation cannulation mode, n (%)	
Venoarterial	145 (40.5)
Venovenous	96 (26.8)
Both venoarterial and venovenous	19 (5.3)
Not reported	98 (27.4)
Maternal overall survival at 30 d, n (%)	
Antepartum	65 (81.2)
Immediate postpartum	58 (84.1)
Postpartum	85 (67.5)
Timeframe unspecified	62 (75.6)
Maternal overall survival at 1 y, n (%)	
	266 (74.3)
Maternal complications, n (%)†	
Mild to moderate bleeding	66 (18.4)
Severe bleeding requiring surgical intervention (laparotomy, hysterectomy)	48 (13.4)
Intracranial neurologic morbidity	19 (5.3)
Vascular complications (extremity ischemia, infection)	14 (3.9)
Deep vein thrombosis	10 (2.8)
Other (peripheral neuropathy, need for rehabilitation on discharge, hyperbilirubinemia, reperfusion injury, bradycardia with cannulation)	22 (6.1)
Fetal survival, n (%)	
	44 (64.7)
Fetal complications, n (%)†	
Preterm delivery	33 (48.5)
Neonatal intensive care unit admission	19 (27.9)

*Some cases had multiple indications for ECLS.

†Some cases had multiple complications.

the patient characteristics. There were a total of 358 cases of ECLS during the peripartum period reported. The maternal survival at 30 days was 270 (75.4%) patients; maternal survival at 1 year was 266 (74.3%). Of the 358 cases, there were 210 (58.7%) cases that described the fetal outcome. There were 81 cases where the mother was on ECLS during pregnancy; of these cases, 68 (84.0%) had fetal outcomes reported. Fetal survival reported for patients who underwent ECLS during the antepartum period was 44 (64.7%) patients.

The most common indications for ECLS overall in pregnancy included ARDS 177 (49.4%), cardiac failure 67 (18.7%), and cardiac arrest 57 (15.9%). Table 2 reports the survival of patients based on indication for ECLS. The most common maternal complications included mild to moderate bleeding 66 (18.4%), severe bleeding requiring surgical intervention 48 (13.4%), and intracranial neurologic morbidity 19 (5.3%). There were 18 (5.0%) patients who had peripheral neurologic deficits or required rehabilitation resulting in an intact neurologic maternal survival of 245 (68.4%).

Table 2. Extracorporeal Life Support Indications and Outcomes

	Total, n (%)	Survival, n (%)
Indications		
Acute respiratory distress syndrome	177 (49.3)	141 (79.7)
Cardiac failure	67 (18.7)	52 (77.6)
Cardiac arrest	57 (15.9)	50 (87.7)
Peripartum cardiomyopathy	45 (12.5)	36 (78.3)
Pulmonary arterial hypertension	28 (7.8)	14 (50)
Amniotic fluid embolism	27 (7.5)	14 (51.9)
Pulmonary embolism	17 (4.7)	11 (64.7)
Heart disease	14 (3.9)	11 (78.6)
Septic shock	11 (3.1)	10 (90.9)

Outcomes separated by indication for extracorporeal support.

There were 81 (22.6%) cases in the antepartum period, 69 (19.3%) cases in the immediately postpartum period (<1 day), and 126 (35.2%) cases in the postpartum period (1–42 days). There were 82 (22.9%) cases that could not be classified into a defined time period. The most common antepartum indications were ARDS 53 (65.4%), cardiac failure 8 (9.9%), pulmonary arterial hypertension 7 (8.6%), and cardiac arrest 7 (8.6%). Complications included mild to moderate bleeding 27 (33.3%) and severe bleeding 7 (8.6%). Cannulation was venovenous in 46 (56.8%), venoarterial in 21 (25.9%), venoarterial+venovenous in 5 (6.2%), and unknown in 9 (11.1%). The average duration of ECLS was 10.8 days. Maternal survival was 65 (80.2%), fetal survival was 44 (64.7%). The most commonly reported fetal complications include preterm delivery 33 (48.5%) and neonatal intensive care unit admission 19 (27.9%). Fetal neurologic complications included intraventricular hemorrhage 2 (2.9%), ventriculomegaly 1 (1.5%), ventriculomegaly/cerebral ischemia 1 (1.5%), and asphyxia with therapeutic hypothermia 1 (1.5%).

The most common immediately postpartum indications included cardiac arrest 39 (56.6%), cardiac failure 16 (23.2%), and amniotic fluid embolism 15 (21.7%). Complications included mild to moderate bleeding 17 (24.6%) and severe bleeding 18 (26.1%). Cannulation was venoarterial in 53 (76.8%), venovenous in 6 (8.7%), venoarterial+venovenous in 6 (8.7%), and unknown in 4 (5.8%). The average duration of ECLS was 5.5 days and maternal survival was 58 (84.1%).

The most common postpartum indications were ARDS 50 (39.7%), peripartum cardiomyopathy 32 (25.4%), and cardiac failure 24 (19.0%). Complications included mild to moderate bleeding 17 (13.5%) and severe bleeding 18 (14.3%). Cannulation was venoarterial in 63 (50%), venovenous in 37 (29.4%), venovenous+venoarterial in 7 cases (5.6%), and unknown in 19 (15.1%). The average duration of ECLS was 17.9 days and maternal survival was 85 (67.5%).

There were 35 deliveries on ECLS at an average gestational age of 26.3 weeks. Women who had deliveries on ECLS had a survival of 27 (79.4%) and of the reported fetal outcomes, the fetal survival was 18 (56.3%). There were 14 (41.2%) vaginal deliveries, 1 (2.9%) vacuum-assisted vaginal delivery, and 20 (57.1%) cesarean deliveries. Of the deliveries on ECLS, 16 (45.7%) were performed with the patient on anticoagulation including 10 (63%) cesarean deliveries and 6 vaginal deliveries (37%). Anticoagulation was held for the delivery in 3 (8.6%) cases and 16 (45.7%) did not explicitly outline anticoagulation management. Additional details on these cases can be found in Table S2. There were 11 cases including cardiopulmonary bypass pre- or post-ECLS. Additional details on these cases can be found in Table S3.

We also analyzed cases based on the cannulation mode as seen in Table 3. Extracorporeal carbon dioxide removal removal 4 (1.1%), extracorporeal arteriovenous carbon dioxide removal removal 1 (0.28%), interventional lung assist membrane 2 (0.56%), and percutaneous extracorporeal lung assist 1 (0.28%) were included within the venovenous cases. Venoarterial cases were more likely to be of shorter duration (average 6.9 days) and for cases of cardiac arrest (28.3%), cardiac failure (26.2%) or peripartum cardiomyopathy (25.5%). Venovenous cases were on average longer in duration (average 18.8 days) and the vast majority were indicated for ARDS 74 (77.1%) followed by asthma 6 (6.25%) and cardiac failure 4 (4.2%). A smaller percentage of patients (5.3%) had both venoarterial or venovenous at different times during the peripartum period and this was most frequently used for cardiac arrest 6 (31.6%), ARDS 6 (31.6%), or cardiac failure 4 (21.1%). The survival between these groups as well as reports where the cannulation mode was unknown was comparable.

DISCUSSION

In this study, we found an overall 30-day survival rate of 75.4% (n=270) for mothers requiring ECLS and a survival rate of 64.7% (n=44) for fetuses exposed to ECLS. However, our fetal survival rate is limited by missing fetal outcomes and lack of long-term follow-up. Complications associated with ECLS in pregnant patients were consistent with the general population including bleeding, deep vein thrombosis, and vascular complications.^{13–15} The indications for ECLS and cannulation methods varied based on the timing relative to delivery. From the few reviews published to date, the survival rate for pregnant patients undergoing ECLS has been significantly higher than the overall survival with adult ECLS for pulmonary (59%) or cardiac (43%) causes¹⁶ with reported maternal survival rates ranging from 70% to 80%^{7–10} and reported fetal survival rates 65% to 72%.^{7–10}

Despite concerns that pregnant or immediately postpartum women may be at risk of bleeding

Table 3. Cannulation Outcomes

	Total, n (%)		Total, n (%)
Venoarterial	145 (40.5)	Venoarterial+Venovenous	19 (5.3)
Indications		Indications	
Cardiac arrest	41 (28.3)	Cardiac arrest	6 (31.6)
Cardiac failure	39 (26.9)	ARDS	6 (31.6)
Peripartum cardiomyopathy	37 (25.5)	Cardiac failure	4 (21.1)
Duration	6.9 d	Duration	13.9 d
Maternal survival	105 (72.4)	Maternal survival	14 (73.7)
Maternal complications		Maternal complications	
Mild to moderate bleeding	29 (20.0)	Mild to moderate bleeding	6 (31.6)
Severe bleeding	23 (15.9)	Severe bleeding	5 (26.3)
Intracranial complications	10 (6.9)	Vascular complications	3 (15.8)
Venovenous	96 (26.8)	Unknown Cannulation	98 (27.4)
Indications		Indications	
ARDS	74 (77.1)	ARDS	83 (84.7)
Asthma	7 (7.3)	Cardiac failure	20 (20.4)
Cardiac failure	4 (4.2)	Cardiac arrest	7 (7.1)
Duration	18.8 d	Duration	12.7 d
Maternal survival	77 (80.2)	Maternal survival	74 (76.3)
Maternal complications		Maternal complications	
Mild to moderate bleeding	29 (30.2)	Mild to moderate bleeding	4 (4.1)
Severe bleeding	12 (12.5)	Severe bleeding	8 (8.2)
Intracranial complications	6 (6.3)	Deep vein thrombosis	5 (5.1)

Indications and outcomes separated by cannulation type. ARDS indicates acute respiratory distress syndrome.

complications and/or at risk for thromboembolic phenomenon in the immediate postpartum period, our findings do not reflect this concern and suggest that the conditions leading these women to require ECLS may be reversible and in fact, more amenable to mechanical support than the standard adult ECLS. Mild to moderate bleeding complications were noted in 18.4% (n=66) of cases and severe bleeding requiring operation was present in 13.4% (n=48) of cases; this was comparable to the reported range in other adults studies ranging from 28% to 32%.¹³⁻¹⁵ Deep vein thromboses and vascular complications were uncommon at 2.8% (n=10) and 3.9% (n=14) respectively and comparable to the ranges reported for limb ischemia in other adult populations, 2% to 14%.^{13-15,17} Collectively, our findings demonstrate that pregnant patients had more favorable survival than prior reported rates for the general population with similar rates of complications.^{13-15,17} These patients represent an overall younger, healthier group who are more likely to have ECLS for acute, reversible indications than the general population of ECLS cases and our findings reflect this underlying favorability for better outcomes.

Survival varied depending on the indication for ECLS. Women who were cannulated for cardiac arrest

had a survival rate of 87.7%; comparing this with a population-based study on maternal cardiac arrest that reported a 58.9% survival suggests that ECLS may have a role in improving clinical outcomes in this context.¹⁸ Neurologically intact survival for patients who undergo extracorporeal cardiopulmonary resuscitation has been reported at 28.5%, in this study it was found to be 78.9% with neurologic deficits including hemiparesis 1 (1.8%), limb motor deficits 2 (3.5%), hand weakness 1 (1.8%), and need for rehabilitation on discharge 2 (3.5%).¹⁹ The current literature regarding amniotic fluid embolism reports a wide range of survival from 39% to 89%.²⁰⁻²² This review found an overall survival of 51.9% (n=14), consistent with the current literature; however, the rate of neurologically intact survival was 74% (n=20) compared with 15% in previously reported literature.²⁰ Pulmonary arterial hypertension has a very poor prognosis in pregnant women and prior case series have reported very poor survival rates with ECLS (16.7%); however, our study reported a survival of 50% (n=14).²³ Several reports of antepartum placement of venous and arterial sheaths for potential rapid initiation of ECLS in patients with severe pulmonary arterial hypertension suggest that these anticipatory interventions may improve outcomes in these high-risk patients.^{24,25}

We separated peripartum patients who underwent ECLS into 3 time periods and observed that there were different indications and survival rates for advanced mechanical support at different stages of pregnancy. The majority of cases during the antepartum period were for cases of ARDS and roughly one-third of those patients delivered while on ECLS. The decision to deliver the neonate versus continue ECLS in these patients is one that requires multidisciplinary discussion and is made on an individual basis depending on the disease process, evolution of illness, institutional experience, and expert opinion. Notably, survival in the immediately postpartum group was highest at 84.1% (n=58). The higher risk of bleeding in the immediately postpartum group (mild to moderate bleeding 17 [24.6%] and severe bleeding 18 [26.1%]) may not be surprising given the number of cases associated with amniotic fluid embolism and postpartum hemorrhage, 2 pathologies known to induce coagulopathy and hyperfibrinolysis. Of the 3 groups, postpartum ECLS had the longest average duration of support and lowest survival rates.

Cardiac arrest was the most common indication in the immediately postpartum period and many of these reports are cases of extracorporeal cardiopulmonary resuscitation, defined as application of venoarterial ECMO during cardiopulmonary resuscitation. The 57 cases of cardiac arrest in this review had very favorable survival (87.7%) compared with the general adult population survival with extracorporeal cardiopulmonary resuscitation (29%).¹⁶ These findings support consideration and use of extracorporeal cardiopulmonary resuscitation in pregnant and immediately postpartum patients as an advantageous group.

Our study has several limitations. These results may be confounded by publication bias as authors may be more likely to report favorable outcomes than poor ones. It may be that the current literature is unduly optimistic with successful cases being overrepresented but could also be underreporting of uneventful but successful cases. Another limitation is that the current data come from case reports and case series. We considered estimating our outcomes using 95% CIs; however, we did not have an unexposed population without ECLS in order to compare our outcomes. Additionally, when calculating CIs to estimate a risk/proportion, there is also the underlying assumption that the observations come from the same population with the same “true” risk and that these are randomly drawn from the population. We rejected this assumption as there is likely to be publication bias when synthesizing results from case reports and case series. Sample size limitations were also a major concern in the consideration of fitting a random effects model. Therefore, we included only the proportion of what is reported in the literature in our sample. There were 4 (1.1%) cases in which the authors noted maternal deaths more than

30 days postpartum that were included to estimate a 1-year maternal survival, however, outcomes at 1 year were not uniformly followed nor reported and this may be an underestimation. We are unable to draw any conclusions about maternal survival over time because of the limited reports prior to 2009. However, the contemporary reports from 2009 to 2019 have a maternal survival rate of 75%. Prospective and detailed reporting with multicenter collaboration may help to better evaluate the use of ECLS in pregnancy including indications, complications, outcomes, and best management strategies for this unique population.

The findings of this study are encouraging but one also has to consider the long-term functional outcomes in these patients. Although studies suggest that patients who have undergone ECMO are able to achieve reasonable physical and neuropsychologic recovery, functional deficits may persist.^{26–30} This is an important consideration in this young population as they may benefit from targeted medical or psychosocial rehabilitation.³¹ Intracranial neurologic morbidity occurred in 5.3% (n=19) of patients and overall neurologically intact survival in this study was 68.4% (n=245). These findings suggest a lower incidence of poor neurologic outcome and mortality compared with other ECMO studies that cite neurologic morbidity in up to 16.0% of patients.^{17,19,32,33} Another limitation to this study is the lack of information on fetal outcomes as they were only reported in 84.0% (n=68) of antepartum cases. With these data alone, it is challenging to accurately predict the fetal risk portended with maternal ECLS. Prospective studies may better elucidate the association of maternal and fetal outcomes with ECLS use during pregnancy.

These limitations notwithstanding, our findings prompt providers to consider the use of ECLS during the peripartum period as a potentially lifesaving intervention for patients with cardiac and/or respiratory failure. Centers that manage high-risk pregnancies, particularly those that include women with congenital heart disease, cardiovascular disease, and/or severe respiratory illness, should be prepared to initiate and manage patients with ECLS in the event of a devastating cardiopulmonary event during the peripartum period.

CONCLUSIONS

ECLS in the peripartum period has been successfully utilized with a maternal survival rate of 75.4% and should be considered in catastrophic cardiopulmonary conditions. Pregnancy brings a set of challenges and unique considerations for ECLS. At present, there are no formal guidelines to lead physicians to best manage these patients and future directions of research include optimal anticoagulation strategies, choice of cannulation sites, fetal monitoring, and/or method and timing of delivery. Future studies may want to assess long-term

outcomes of neonates born to women who underwent ECLS during the antepartum period. Moving forward, to more clearly assess outcomes, an emphasis should be made on reporting all cases of ECLS in pregnancy in a prospective manner with more granular case details to establish an inclusive assessment of outcomes and complications in this unique population.

ARTICLE INFORMATION

Received February 13, 2020; accepted May 14, 2020.

Affiliations

From the Department of Anesthesiology (E.E.N., M.M., M.E.B.), Department of Anesthesia, Critical Care and Pain Medicine Massachusetts General Hospital, Boston, MA (A.C.); Department of Cardiac Surgery University of Michigan, Ann Arbor, MI (J.H.); Taubman Health Sciences Library, Ann Arbor, MI (M.M.); Department of Obstetrics and Gynecology, Maternal-Fetal Medicine (C.J.V.), Division of Maternal-Fetal Medicine, Department of Obstetrics and Gynecology, Brigham and Women's Hospital (S.R.E.) and Division of Pharmacoepidemiology and Pharmacoeconomics, Department of Medicine, Department of Anesthesiology, Perioperative and Pain Medicine, Brigham and Women's Hospital, Boston, MA (B.T.B.)

Acknowledgments

The authors would like to thank Dana Rector, Madeline McCabe, Dana Labuda, and Jasmine Purtell (Research Assistants, University of Michigan, funded by the Department of Anesthesiology) for their administrative assistance with this systematic review and Ruth Cassidy (Senior Statistician, University of Michigan, funded by the Department of Anesthesiology) for her assistance with statistical consultation with this review.

Sources of Funding

This work was supported by the University of Michigan Department of Anesthesiology.

Disclosures

None.

Supplementary Materials

Data S1

Tables S1–S3

References 7, 8, 9, 23, and 34–250

REFERENCES

- Creanga AA, Syverson C, Seed K, Callaghan WM. Pregnancy-related mortality in the United States, 2011–2013. *Obstet Gynecol*. 2017;130:366–373.
- Severe maternal morbidity in the United States. 2019.
- Joseph KS, Lisonkova S, Muraca GM, Razaz N, Sabr Y, Mehrabadi A, Schisterman EF. Factors underlying the temporal increase in maternal mortality in the United States. *Obstet Gynecol*. 2017;129:91–100.
- Agrawal P. Maternal mortality and morbidity in the United States of America. *Bull World Health Organ*. 2015;93:135.
- Leonard SA, Main EK, Carmichael SL. The contribution of maternal characteristics and cesarean delivery to an increasing trend of severe maternal morbidity. *BMC Pregnancy Childbirth*. 2019;19:16.
- Bateman BT, Bansil P, Hernandez-Diaz S, Mhyre JM, Callaghan WM, Kuklina EV. Prevalence, trends, and outcomes of chronic hypertension: a nationwide sample of delivery admissions. *Am J Obstet Gynecol*. 2012;206:134.e1–8.
- Moore SA, Dietl CA, Coleman DM. Extracorporeal life support during pregnancy. *J Thorac Cardiovasc Surg*. 2016;151:1154–1160.
- Sharma NS, Wille KM, Bellot SC, Diaz-Guzman E. Modern use of extracorporeal life support in pregnancy and postpartum. *ASAIO J*. 2015;61:110–114.
- Anselmi A, Ruggieri VG, Lethuille J, Robert AL, Tomasi J, Le Tulzo Y, Verhoye JP, Flecher E. Extracorporeal membrane oxygenation in pregnancy. *J Card Surg*. 2015;30:781–786.
- Saad AF, Rahman M, Maybauer DM, Fraser JF, Costantine MM, Pacheco LD, Maybauer MO. Extracorporeal membrane oxygenation in pregnant and postpartum women with H1N1-related acute respiratory distress syndrome: a systematic review and meta-analysis. *Obstet Gynecol*. 2016;127:241–247.
- Moher D, Liberati A, Tetzlaff J, Altman DG. Preferred reporting items for systematic reviews and meta-analyses: the PRISMA statement. *J Clin Epidemiol*. 2009;62:1006–1012.
- Levels of neonatal care. *Pediatrics*. 2012;130:587–597.
- Swol J, Brodie D, Napolitano L, Park PK, Thiagarajan R, Barbaro RP, Lorusso R, McMullan D, Cavarocchi N, Hssain AA, et al. Indications and outcomes of extracorporeal life support in trauma patients. *J Trauma Acute Care Surg*. 2018;84:831–837.
- Haas NL, Coute RA, Hsu CH, Cranford JA, Neumar RW. Descriptive analysis of extracorporeal cardiopulmonary resuscitation following out-of-hospital cardiac arrest—an ELSO registry study. *Resuscitation*. 2017;119:56–62.
- Yeo HJ, Kim D, Jeon D, Kim YS, Rycus P, Cho WH. Extracorporeal membrane oxygenation for life-threatening asthma refractory to mechanical ventilation: analysis of the Extracorporeal Life Support Organization registry. *Crit Care*. 2017;21:297.
- ELSO registry report. July 2019.
- Wang L, Wang H, Hou X. Clinical outcomes of adult patients who receive extracorporeal membrane oxygenation for postcardiomy cardiogenic shock: a systematic review and meta-analysis. *J Cardiothorac Vasc Anesth*. 2018;32:2087–2093.
- Mhyre JM, Tsen LC, Einav S, Kuklina EV, Leffert LR, Bateman BT. Cardiac arrest during hospitalization for delivery in the United States, 1998–2011. *Anesthesiology*. 2014;120:810–818.
- Ryu JA, Chung CR, Cho YH, Sung K, Jeon K, Suh GY, Park TK, Lee JM, Song YB, Hahn JY, et al. Neurologic outcomes in patients who undergo extracorporeal cardiopulmonary resuscitation. *Ann Thorac Surg*. 2019;108:749–755.
- Clark SL, Hankins GD, Dudley DA, Dildy GA, Porter TF. Amniotic fluid embolism: analysis of the national registry. *Am J Obstet Gynecol*. 1995;172:1158–1167; discussion 1167–9.
- Benson MD. Amniotic fluid embolism mortality rate. *J Obstet Gynaecol Res*. 2017;43:1714–1718.
- Knight M, Berg C, Brocklehurst P, Kramer M, Lewis G, Oats J, Roberts CL, Spong C, Sullivan E, van Roosmalen J, et al. Amniotic fluid embolism incidence, risk factors and outcomes: a review and recommendations. *BMC Pregnancy Childbirth*. 2012;12:7.
- Meng ML, Landau R, Viktorsdottir O, Banayan J, Grant T, Bateman B, Smiley R, Reitman E. Pulmonary hypertension in pregnancy: a report of 49 cases at four tertiary north American sites. *Obstet Gynecol*. 2017;129:511–520.
- Minicucci S, Segala V, Verdecchia C, Sismondi P, Casabona P, Sansone F. Safe management of cesarean section in a patient of Eisenmenger syndrome. *Ann Card Anaesth*. 2012;15:296–298.
- Rosenzweig EB, Biscotti M, Cleary K, Smiley R, Bacchetta MD. Chronic thromboembolic pulmonary hypertension, pregnancy, and a pulmonary endarterectomy: a rare challenge. *Pulm Circ*. 2016;6:384–388.
- Norkiene I, Jovaisa T, Scupakova N, Janusauskas V, Rucinskas K, Serpytis P, Laurusonis K, Samalavicius R. Long-term quality of life in patients treated with extracorporeal membrane oxygenation for post-cardiotomy cardiogenic shock. *Perfusion*. 2019;34:285–289.
- Sylvestre A, Adda M, Maltese F, Lannelongue A, Daviet F, Parzy G, Coiffard B, Roch A, Loundou A, Baumstarck K, et al. Long-term neurocognitive outcome is not worsened by the use of venovenous ECMO in severe ARDS patients. *Ann Intensive Care*. 2019;9:82.
- Grasselli G, Scaravilli V, Tubiolo D, Russo R, Crimella F, Bichi F, Corinna Morlacchi L, Scotti E, Patrini L, Gattinoni L, et al. Quality of life and lung function in survivors of extracorporeal membrane oxygenation for acute respiratory distress syndrome. *Anesthesiology*. 2019;130:572–580.
- von Bahr V, Kalzen H, Hultman J, Frenckner B, Andersson C, Mosskin M, Eksborg S, Holzgraebe B. Long-term cognitive outcome and brain imaging in adults after extracorporeal membrane oxygenation. *Crit Care Med*. 2018;46:e351–e358.
- Roll MA, Kuys S, Walsh JR, Tronstad O, Ziegenfuss MD, Mullany DV. Long-term survival and health-related quality of life in adults after extra corporeal membrane oxygenation. *Heart Lung Circ*. 2019;28:1090–1098.

31. Combes A, Leprince P, Luyt CE, Bonnet N, Trouillet JL, Leger P, Pavie A, Chastre J. Outcomes and long-term quality-of-life of patients supported by extracorporeal membrane oxygenation for refractory cardiogenic shock. *Crit Care Med*. 2008;36:1404–1411.
32. Klinzing S, Wenger U, Stretti F, Steiger P, Rushing EJ, Schwarz U, Maggiorini M. Neurologic injury with severe adult respiratory distress syndrome in patients undergoing extracorporeal membrane oxygenation: a single-center retrospective analysis. *Anesth Analg*. 2017;125:1544–1548.
33. Lorusso R, Barili F, Mauro MD, Gelsomino S, Parise O, Rycus PT, Maessen J, Mueller T, Muellenbach R, Belohlavek J, et al. In-hospital neurologic complications in adult patients undergoing venoarterial extracorporeal membrane oxygenation: results from the extracorporeal life support organization registry. *Crit Care Med*. 2016;44:e964–e972.
34. Abbal B, Perbet S, Jabaudon M, Legault B, Gallot D, Constantin JM. [Extracorporeal membrane oxygenation for refractory hypoxia secondary to a severe viral pneumonia due to influenza A (H1N1) in a pregnant woman: continuation or termination of pregnancy?]. *Ann Fr Anesth Reanim*. 2014;33:55–57.
35. Abid Memon H, Safdar Z, Goodarzi A. Use of extracorporeal membrane oxygenation in postpartum management of a patient with pulmonary arterial hypertension. *Case Rep Pulmonol*. 2018;2018:7031731.
36. Agerstrand C, Abrams D, Biscotti M, Moroz L, Rosenzweig EB, D'Alton M, Brodie D, Bacchetta M. Extracorporeal membrane oxygenation for cardiopulmonary failure during pregnancy and postpartum. *Ann Thorac Surg*. 2016;102:774–779.
37. Alamo M, Castro J, Alvarez E, Brunet L. [Extracorporeal membrane oxygenation in adult respiratory distress syndrome. Experience in 2 patients]. *Rev Med Chil*. 1995;123:1275–1283.
38. Alyamani O, Mazzeffi MA, Bharadwaj S, Galey JH, Yao R, Shah NG, Malinow AM. Venovenous extracorporeal membrane oxygenation to prolong pregnancy: a case report. *A A Pract*. 2018;10:229–231.
39. Amancio RT, Acra CM, Souza Dantas VC. Extra-corporeal membrane oxygenation as an indispensable tool for a successful treatment of a pregnant woman with H1N1 infection in Brazil. *Respir Med Case Rep*. 2017;20:133–136.
40. Arlt M, Philipp A, Iesalnieks I, Kobuch R, Graf BM. Successful use of a new hand-held ECMO system in cardiopulmonary failure and bleeding shock after thrombolysis in massive post-partal pulmonary embolism. *Perfusion*. 2009;24:49–50.
41. Barbalic B, Tokmadzic VS, Petrovic O, Kricka IB, Sustic A. Life saving use of ECMO in an obstetric patient with massive hemorrhage following uterine atony: a case report. *Signa Vitae*. 2016;12:121–124.
42. Barnes L, Passarelli PJ, Hsiao R, Sell RE. Surfactant protein C deficiency and rheumatoid arthritis interstitial lung disease in pregnancy—a fatal combination. *Am J Respir Crit Care Med*. 2018;197:A1541. MeetingAbstracts.
43. Bartlett RH, Gazzaniga AB, Fong SW, Burns NE. Prolonged extracorporeal cardiopulmonary support in man. *J Thorac Cardiovasc Surg*. 1974;68:918–932.
44. Bataillard A, Hebrard A, Gaide-Chevronnay L, Casez M, Dessertaine G, Durand M, Chavanon O, Albaladejo P. Extracorporeal life support for massive pulmonary embolism during pregnancy. *Perfusion*. 2016;31:169–171.
45. Ortiz-Bautista C, Lopez-Gude MJ, Grande Garcia J, Perez-Vela JL, Perez-Gonzalez V, Escribano-Subias P. Extracorporeal membrane oxygenation support during pregnancy in pulmonary veno-occlusive disease. *Rev Esp Cardiol*. 2018;07:07.
46. Bellissima P, Bellissima G. [Pulmonary complications from pandemic AH1N1 influenza: clinical-radiological features]. *Infez Med*. 2011;19:20–27.
47. Benetis R, Nadisauskiene R, Sirvinskas E, Lenkutis T, Siudikas A, Kadusauskaitė V, Railaitė D, Sukovas A, Abraitis V. Successfully treated severe obstetric sepsis and acute respiratory distress syndrome with extracorporeal membrane oxygenation. *Perfusion*. 2016;31:343–346.
48. Besnier E, Hubscher C, Doguet F, Bessou JP, Dureuil B. [Extracorporeal membrane oxygenation support for tako-tsubo syndrome after urgent caesarean section]. *Ann Fr Anesth Reanim*. 2013;32:704–706.
49. Beurtheret S, Mordant P, Paoletti X, Marjion E, Celermajer DS, Leger P, Pavie A, Combes A, Leprince P. Emergency circulatory support in refractory cardiogenic shock patients in remote institutions: a pilot study (the cardiac-RESCUE program). *Eur Heart J*. 2013;34:112–120.
50. Biderman P, Carmi U, Setton E, Fainblut M, Bachar O, Einav S. Maternal salvage with extracorporeal life support: lessons learned in a single center. *Anesth Analg*. 2017;125:1275–1280.
51. Bok JS, Jun JH, Lee HJ, Park IK, Kang CH, Yang J, Kim YT. A successful bilateral lung transplantation in a patient with high panel reactive antibody and positive cross matching. *Korean J Thorac Cardiovasc Surg*. 2014;47:420–422.
52. Bouabdallaoui N, Demondion P, Leprince P, Lebreton G. Short-term mechanical circulatory support for cardiogenic shock in severe peripartum cardiomyopathy: La Pitie-Salpêtrière experience. *Interact Cardiovasc Thorac Surg*. 2017;25:52–56.
53. Bowkallow S, Brauer M, Gross W, Schleussner E. Severe H1N1-infection during pregnancy. *Arch Gynecol Obstet*. 2011;284:1133–1135.
54. Bruch C, Paraforos A, Kunitz O. [Case report: extracorporeal life support for treatment of fulminant pulmonary embolism in a young woman during pregnancy]. *Anesthesiol Intensivmed Notfallmed Schmerzther*. 2013;48:682–684.
55. Cerene A, Barthelemy R, Vives M. Respiratory support by long term extracorporeal circulation (with a report of a successfully treated case of Mendelson's syndrome). *Ann Chir*. 1977;31:35–37.
56. Chambers J, Smith N, Sehring M, Chittivelu S. Acute chest syndrome progressing to ARDS in a patient of 25-week gestation. *Case Rep Crit Care*. 2018;2018:4243569.
57. Champion S, Belcour D, Gaüzère BA. Thrombotic thrombocytopenic purpura presenting as a severe peripartum cardiogenic shock: role of myocardial biopsy and assist device for diagnosis and resuscitation. *Eur Heart J Acute Cardiovasc Care*. 2017;2048872617740829.
58. Chao AS, Chang YL, Lien R, Tsai FC, Wu TS, Chiu TF, Chao A. Successful childbirth after extracorporeal membrane oxygenation in previous pregnancy: two case reports. *Eur J Obstet Gynecol Reprod Biol*. 2016;198:168–169.
59. Chehab O, Simon A. Rapid onset cardiogenic shock secondary to a case of peripartum cardiomyopathy. *Eur J Heart Fail*. 2015;17(suppl 1):22–23.
60. Chillcott S, Sheridan PS. ECCO2R: an experimental approach to treating ARDS. *Crit Care Nurse*. 1995;15:50–56.
61. Cho FN, Chen SN. Use of extracorporeal membrane oxygenation to manage post-partum pulmonary haemorrhage associated with pulmonary hypertension and aberrant right pulmonary artery. *Aust N Z J Obstet Gynaecol*. 2006;46:556–558.
62. Choi CW, Lim JW, Kim TH. Re: microcirculation in women with severe pre-eclampsia and HELLP syndrome: a case control study: effect of timing of extracorporeal membrane oxygenation during HELLP syndrome. *BJOG*. 2016;123:1710.
63. Chuang CJ, Hsu CS. Successful application of extracorporeal membrane oxygenation and pulmonary thromboembolism in a patient with a life-threatening pulmonary embolism. *Taiwan J Obstet Gynecol*. 2015;54:467–468.
64. Clark GP, Dobson PM, Thickett A, Turner NM. Chickenpox pneumonia, its complications and management. A report of three cases, including the use of extracorporeal membrane oxygenation. *Anaesthesia*. 1991;46:376–380.
65. Clifford C, Mhatre M, Craigo S. Successful use of extracorporeal membrane oxygenation for status asthmaticus in a woman with a periviable pregnancy. *Obstet Gynecol*. 2018;17:17.
66. Coscia AP, Cunha HF, Longo AG, Martins EG, Saddy F, Japiassu AM. Report of two cases of ARDS patients treated with pumpless extracorporeal interventional lung assist. *J Bras Pneumol*. 2012;38:408–411.
67. Courouble P, Geukens P, Laarbaui F, Beauloye C, Van Caenegem O, Jacquet LM. Adult respiratory distress syndrome caused by 2009 H1N1 influenza during pregnancy: success of ECMO for both the mother and the child. *J Extra Corpor Technol*. 2011;43:75–78.
68. Crawford TC, Grimm JC, Magruder JT, Stephens RS, Sciortino CM, Vaught AJ, Althaus J, Shah AS, Kim BS. A curious case of acute respiratory distress syndrome. *J Surg Case Rep*. 2015;11:09.
69. Creanga AA, Johnson TF, Graitcer SB, Hartman LK, Al-Samarrai T, Schwarz AG, Chu SY, Sackoff JE, Jamieson DJ, Fine AD, et al. Severity of 2009 pandemic influenza A (H1N1) virus infection in pregnant women. *Obstet Gynecol*. 2010;115:717–726.
70. Cunningham JA, Devine PC, Jelic S. Extracorporeal membrane oxygenation in pregnancy. *Obstet Gynecol*. 2006;108:792–795.
71. Dabas N, MacOn C, Loebe M, Brozzi N, Ghodsizad A, Badiye A. Transposition of the great arteries, pregnancy, cardiac arrest and ECMO: a challenging case. *J Am Coll Cardiol*. 2018;71(11 supplement 1):A2476.
72. Di Lorenzo G, Martucci G, Sciacca S, Longo R, Pilato M, Arcadipane A. Dysfunction of mechanical mitral prosthesis at 33rd week of

- pregnancy: ECMO support as a complex strategy for the mother and the fetus. *Perfusion*. 2016;31:611–613.
73. Ecker JL, Solt K, Fitzsimons MG, MacGillivray TE. Case records of the Massachusetts General Hospital. Case 40-2012. A 43-year-old woman with cardiorespiratory arrest after a cesarean section. *N Engl J Med*. 2012;367:2528–2536.
 74. Ellington SR, Hartman LK, Acosta M, Martinez-Romo M, Rubinson L, Jamieson DJ, Louie J. Pandemic 2009 influenza A (H1N1) in 71 critically ill pregnant women in California. *Am J Obstet Gynecol*. 2011;204:S21–S30.
 75. Erb CT, Black JD. Successful treatment of severe peripartum cardiomyopathy with intra-aortic balloon pump (IABP), biventricular assist device (BiVAD), and extra-corporeal membrane oxygenation (ECMO). *Am J Respir Crit Care Med*. 2013;187:A4430.MeetingAbstracts.
 76. Evans R. Post-partum spontaneous coronary artery dissection and the use of veno-arterial extra-corporeal membrane oxygenation. *Nurs Crit Care*. 2014;19:304–309.
 77. Ezri T, Golan A, Sasson L, Rozenman Y. Pheochromocytoma induced fulminant cardiogenic shock following laparoscopic salpingectomy, successfully managed with extracorporeal membrane oxygenation. *Jurnalul Roman de Anestezie Terapie Intensiva*. 2009;16:154–158.
 78. Fabricius AM, Autschbach R, Doll N, Mohr W. Acute aortic dissection during pregnancy. *Thorac Cardiovasc Surg*. 2001;49:56–57.
 79. Faerber G, Kirov H, Sandhaus T, Doenst T. Successful weaning and explantation of the HeartMate3 left ventricular assist device using a pre-designed metal plug. *J Heart Lung Transplant*. 2018;37:S288.
 80. Fang ZA, Van Diepen S, Royal Alexandra H and University of Alberta Hospital Cardiac Arrest T. Successful inter-hospital transfer for extra-corporeal membrane oxygenation after an amniotic fluid embolism induced cardiac arrest. *Can J Anaesth*. 2016;63:507–508.
 81. Fayad G, Larrue B, Modine T, Azzaoui R, Regnault A, Koussa M, Gourlay T, Fourrier F, Decoene C, Warembourg H. Extracorporeal membrane oxygenation in severe acute respiratory failure in postpartum woman with rheumatic mitral valve disease: benefit, factors furthering the success of this procedure, and review of the literature. *J Extra Corpor Technol*. 2007;39:112–116.
 82. Fernandes P, Allen P, Valdis M, Guo L. Successful use of extracorporeal membrane oxygenation for pulmonary embolism, prolonged cardiac arrest, post-partum: a cannulation dilemma. *Perfusion*. 2015;30:106–110.
 83. Fernandez L, Sua LF, Garcia L, Velasquez M, Garcia C. A fatal case of giant cell pulmonary sarcomatoid carcinoma diagnosed in a pregnant woman: case report. *Am J Respir Crit Care Med*. 2015;191:A3621. MeetingAbstracts.
 84. Firstenberg MS, Abel E, Blais D, Louis LB, Steinberg S, Sai-Sudhakar C, Martin S, Sun B. The use of extracorporeal membrane oxygenation in severe necrotizing soft tissue infections complicated by septic shock. *Am Surg*. 2010;76:1287–1289.
 85. Fuchs A, McLaren R, Saunders P, Karakash S, Minkoff H. Human metapneumovirus infection and acute respiratory distress syndrome during pregnancy. *Obstet Gynecol*. 2017;130:630–632.
 86. Futoran JM, Hill JD. Pulmonary insufficiency associated with pregnancy. *Am J Obstet Gynecol*. 1975;121:637–640.
 87. Garcia-Aranda Dominguez B, Diaz-Anton B, Villar OP, Garcia-Burquillo A, Hernandez-Gonzalez I, Quezada A, Real MI, Martin-Asenjo R, Lopez-Gude MJ, Escribano-Subias P. Outcome of pregnancy in patients with cardiovascular disease, experience in a centre. *Eur Heart J*. 2017;38(supplement 1):351.
 88. Gattinoni L, Agostoni A, Pesenti A, Pelizzola A, Rossi GP, Langer M, Vesconi S, Uziel L, Fox U, Longoni F, et al. Treatment of acute respiratory failure with low-frequency positive-pressure ventilation and extracorporeal removal of CO₂. *Lancet*. 1980;2:292–294.
 89. Gauzere BA, Bussienne F, Bouchet B, Jabot J, Roussiaux A, Drouet D, Djourhi S, Leaute B, Belcour D, Bossard G, et al. [Severe cases of A (H1N1) v2009 infection in Reunion Island in 2009 and 2010]. *Bull Soc Pathol Exot*. 2011;104:97–104.
 90. Gevaert S, Van Belleghem Y, Bouchez S, Herck I, De Somer F, De Block Y, Tromp F, Vandecasteele E, Martens F, De Pauw M. Acute and critically ill peripartum cardiomyopathy and 'bridge to' therapeutic options: a single center experience with intra-aortic balloon pump, extra corporeal membrane oxygenation and continuous-flow left ventricular assist devices. *Crit Care*. 2011;15:R93.
 91. Gijs J, Lambert J, Meyfroidt G, Demeestere J. Cerebral microbleeds and intracerebral hemorrhage associated with veno-venous extracorporeal membrane oxygenation. *Acta Neurol Belg*. 2018;118:513–515.
 92. Goto M, Watanabe H, Ogita K, Matsuoka T. Perimortem cesarean delivery and subsequent emergency hysterectomy: new strategy for maternal cardiac arrest. *Acute Med*. 2017;4:467–471.
 93. Grasselli G, Bombino M, Patroniti N, Giuffrida A, Marcolin R, Vergani P, Pesenti A. Use of extracorporeal respiratory support during pregnancy: a case report and literature review. *ASAIO J*. 2012;58:281–284.
 94. Greenberg LR, Moore TR. Staphylococcal septicemia and adult respiratory distress syndrome in pregnancy treated with extracorporeal carbon dioxide removal. *Obstet Gynecol*. 1995;86:657–660.
 95. Grimme I, Winter R, Kluge S, Petzoldt M. Hypoxic cardiac arrest in pregnancy due to pulmonary haemorrhage. *BMJ Case Rep*. 2012;24:24.
 96. Guenther SPW, Reichelt A, Buchholz S, Born F, Fischer M, Schramm R, Pichlmaier AM, Hagl C, Khaladj N. Fulminant amniotic fluid embolism. Mobile ECLS team in the delivery ward. *Z Herz Thorax Gefasschir*. 2015;29:312–316.
 97. Guillaume A, Sananes N, Akladios CY, Boudier E, Diemunsch P, Averous G, Nisand I, Langer B. Amniotic fluid embolism: 10-year retrospective study in a level III maternity hospital. *Eur J Obstet Gynecol Reprod Biol*. 2013;169:189–192.
 98. Halldorsdottir H, Nordstrom J, Brattstrom O, Sennstrom MM, Sartipy U, Mattsson E. Early postpartum mitral valve thrombosis requiring extra corporeal membrane oxygenation before successful valve replacement. *Int J Obstet Anesth*. 2016;26:75–78.
 99. Hamdan R, Nassar P, Zein A, Issa M, Mansour H, Saab M. Peripartum cardiomyopathy, place of drug therapy, assist devices, and outcome after left ventricular assistance. *J Crit Care*. 2017;37:185–188.
 100. Hansen AJ, Sorrell VL, Cooper AD, Moulton MJ. Postpartum rupture of the posteromedial papillary muscle. *J Card Surg*. 2012;27:313–316.
 101. Hara R, Hara S, Ong CS, Schwartz G, Sciortino C, Hibino N. Cesarean section in the setting of severe pulmonary hypertension requiring extracorporeal life support. *Gen Thorac Cardiovasc Surg*. 2017;65:532–534.
 102. Herrero T, Martin E, Poch DS, Roeder HA. Anti-coagulation complications in pregnancies with severe pulmonary arterial hypertension. *J Matern Fetal Neonatal Med*. 2018;31:1209–1213.
 103. Hill JD, Ratliff JL, Fallat RJ, Tucker HJ, Lamy M, Dietrich HP, Gerbode F. Prognostic factors in the treatment of acute respiratory insufficiency with long-term extracorporeal oxygenation. *J Thorac Cardiovasc Surg*. 1974;68:905–917.
 104. Ho CH, Chen KB, Liu SK, Liu YF, Cheng HC, Wu RS. Early application of extracorporeal membrane oxygenation in a patient with amniotic fluid embolism. *Acta Anaesthesiol Taiwan*. 2009;47:99–102.
 105. Ho YK, Wang CP, Wu YL, Lee TH, Ying TH, Lee MS. Pulmonary embolism after cesarean section and successful treatment with early application of extracorporeal membrane oxygenation system and anticoagulant agents. *Taiwan J Obstet Gynecol*. 2014;53:273–275.
 106. Holzgraefe B, Broome M, Kalzen H, Konrad D, Palmer K, Frenckner B. Extracorporeal membrane oxygenation for pandemic H1N1 2009 respiratory failure. *Minerva Anesthesiol*. 2010;76:1043–1051.
 107. Hou X, Guo L, Zhan Q, Jia X, Mi Y, Li B, Sun B, Hao X, Li H. Extracorporeal membrane oxygenation for critically ill patients with 2009 influenza A (H1N1)-related acute respiratory distress syndrome: preliminary experience from a single center. *Artif Organs*. 2012;36:780–786.
 108. Hsieh YY, Chang CC, Li PC, Tsai HD, Tsai CH. Successful application of extracorporeal membrane oxygenation and intra-aortic balloon counterpulsation as lifesaving therapy for a patient with amniotic fluid embolism. *Am J Obstet Gynecol*. 2000;183:496–497.
 109. Huang KY, Li YP, Lin SY, Shih JC, Chen YS, Lee CN. Extracorporeal membrane oxygenation application in post-partum hemorrhage patients: is post-partum hemorrhage contraindicated? *J Obstet Gynaecol Res*. 2017;43:1649–1654.
 110. Huang HC, Chang SC, Huang CS. Airway exchange catheter used in a lymphoma patient with acute respiratory failure who failed to be mechanically ventilated. *Am J Respir Crit Care Med*. 2017;195:A3621.
 111. Hur JA. A fatal case in pregnant woman infected by H1N1 2009 in Korea. *Infect Chemother*. 2011;43:225–228.
 112. Imaeda T, Nakada TA, Abe R, Tateishi Y, Oda S. Veno-arterial extra-corporeal membrane oxygenation for *Streptococcus pyogenes* toxic shock syndrome in pregnancy. *J Artif Organs*. 2016;19:200–203.

113. Isbir S, Ak K, Aslantas M, Kepez A, Cinel I, Arsan S. Peripartum cardiomyopathy mimicking acute aortic dissection: successful salvage with extracorporeal membrane oxygenation support. *Turk Gogus Kalp Damar Cerrahisi Derg.* 2014;22:843–846.
114. Itagaki T, Onodera M, Okuda N, Nakataki E, Imanaka H, Nishimura M. Successful use of extracorporeal membrane oxygenation in the reversal of cardiorespiratory failure induced by atonic uterine bleeding: a case report. *J Med Case Rep.* 2014;8:23.
115. lus F, Sommer W, Tudorache I, Avsar M, Siemeni T, Salman J, Puntigam J, Optenhoefel J, Greer M, Welte T, et al. Venovenous-extracorporeal membrane oxygenation for respiratory failure with severe haemodynamic impairment: technique and early outcomes. *Interact Cardiovasc Thorac Surg.* 2015;20:761–767.
116. Jacquens A, Kerever S, Guidet B, Aegerter P, Das V, Cariou A, Fartoukh M, Hayon J, Combes A, De Montmollin E, et al. Pneumonia during pregnancy and the post partum period: a reappraisal of etiologies requiring intermediate or intensive care—a retrospective study through the CUBREA network. *Ann Intensive Care.* 2017;7:177–178.
117. Jais X, Olsson KM, Barbera JA, Blanco I, Torbicki A, Peacock A, Vizza CD, Macdonald P, Humbert M, Hoeper MM. Pregnancy outcomes in pulmonary arterial hypertension in the modern management era. *Eur Respir J.* 2012;40:881–885.
118. Jandhyala R, Haydon P, Czaplacka C, Claprood C, Casey K. Successful vaginal delivery of a male infant during extracorporeal carbon dioxide removal: a case report. *J Extra Corpor Technol.* 1994;26:87–90.
119. Janssen MJ, van de Wetering K, Arabin B. Sepsis due to gestational psittacosis: a multidisciplinary approach within a perinatal center—review of reported cases. *Int J Fertil Womens Med.* 2006;51:17–20.
120. Jo YY, Park S, Choi YS. Extracorporeal membrane oxygenation in a patient with stress-induced cardiomyopathy after caesarean section. *Anaesth Intensive Care.* 2011;39:954–957.
121. John SG, Carr G, Raz Y. Independent ventilation and ECMO for severe refractory pulmonary edema in a pregnant patient with rheumatic mitral stenosis. *Crit Care Med.* 2012;40:U336–U337.
122. Ju YH, Hyun CW, Dong-Hyung L, Gon KH, Jung SY, Sup BK, Seok KH, Hoon YS, Eun LS, Do Hyung K, et al. The role of extracorporeal membrane oxygenation in obstetric emergencies with unexpected refractory shock. *Clin Exp Obstet Gynecol.* 2018;45:466–469.
123. Kapoor A. Pulmonary hypertension (PH) and pregnancy: watch for catastrophe. *Am J Respir Crit Care Med.* 2012;185:A4625. Meeting Abstracts.
124. Kaliyev R, Kapyshev T, Goncharov A, Lesbekov T, Pya Y. Maternal and fetal recovery after severe respiratory failure: a case report of air transportation of a pregnant woman on ECMO using the CentriMag transporter system. *ASAIO J.* 2015;61:e33–e35.
125. King PT, Rosalio A, McMillan J, Buist M, Holmes PW. Extracorporeal membrane oxygenation its pregnancy. *Lancet.* 2000;356:45–46.
126. Kinni H, Hegab S. Uncommon etiology of diffuse alveolar hemorrhage: hereditary hemorrhagic telangiectasia. *Am J Respir Crit Care Med.* 2018;197:A3714. Meeting Abstracts.
127. Knapp KE, Weis RA, Cubillo EI, Chapital AB, Ramakrishna H. Spontaneous, postpartum coronary artery dissection and cardiogenic shock with extracorporeal membrane oxygenation assisted recovery in a 30-year-old patient. *Case Rep Cardiol.* 2016;2016:1048708.
128. Ko WJ, Ho HN, Chu SH. Postpartum myocardial infarction rescued with an intraaortic balloon pump and extracorporeal membrane oxygenator. *Int J Cardiol.* 1998;63:81–84.
129. Konstantinidis K, Schulman S. Peripartum management of severe idiopathic pulmonary arterial hypertension and the use of extracorporeal membrane oxygenation during delivery. *J Am Coll Cardiol.* 2015;65:A646.
130. International Session Workshop (IS-WS). 69th Annual Congress of the Japan Society of Obstetrics and Gynecology. Hiroshima, Japan, 13–16 April, 2017. *J Obstet Gynaecol Res.* 2017;43:1897–1922.
131. Kumar S, Shumaster V, Jacoby DA, Mangi A. BIVAD and ECMO for bridge to recovery in peripartum cardiomyopathy. *Heart Surg Forum.* 2012;15(suppl 1):S109–S110.
132. Krumnikl JJ, Toller WG, Prenner G, Metzler H. Beneficial outcome after prostaglandin-induced post-partum cardiac arrest using levosimendan and extracorporeal membrane oxygenation. *Acta Anaesthesiol Scand.* 2006;50:768–770.
133. Kunstner J, Lips M, Belohlavek J, Prskavec T, Mlejnsky F, Koucky M, Sebron V, Balik M. Spontaneous delivery during venovenous extracorporeal membrane oxygenation in swine influenza-related acute respiratory failure. *Acta Anaesthesiol Scand.* 2010;54:1154–1155.
134. Kutlesa M, Santini M, Krajinovic V, Raffanelli D, Barsic B. Novel observations during extracorporeal membrane oxygenation in patients with ARDS due to the H1N1 pandemic influenza. *Wien Klin Wochenschr.* 2011;123:117–119.
135. Law C, Khaliq A, Guglin M. Reversible cardiogenic shock due to catecholamine-induced cardiomyopathy: a variant of takotsubo? *Am J Emerg Med.* 2013;31:1621.e1–1621.e3.
136. Lee WA, Kolla S, Schreiner RJ Jr, Hirschl RB, Bartlett RH. Prolonged extracorporeal life support (ECLS) for varicella pneumonia. *Crit Care Med.* 1997;25:977–982.
137. Lee AJ, Koyyalamudi PL, Martinez-Ruiz R. Severe transfusion-related acute lung injury managed with extracorporeal membrane oxygenation (ECMO) in an obstetric patient. *J Clin Anesth.* 2008;20:549–552.
138. Legrand M, Rossignol M, Muller F, Payen D. [Amniotic fluid embolism: an update]. *Ann Fr Anesth Reanim.* 2013;32:189–197.
139. Lemaire A, Bonnin M, Storme B, Fournet-Fayard A, Rosano G, Vernis L, Cayot S, Accocebery M, Dechelotte P, Boyer L, et al. Hemoperitoneum in peripartum: a case-series. *J Neonatal Perinatal Med.* 2017;10:451–454.
140. Lembrikov I, Rudis E, Weiniger CF. Postpartum cardiogenic shock diagnosed by focused cardiac ultrasound and treated with venoarterial extracorporeal membrane oxygenation: a case report. *A A Pract.* 2019;12:277–280.
141. Li HL, Du HY, Jiang YH, Zhao YY, Zhu X, Yao GQ. Nine-month follow-up of an acute respiratory distress syndrome caused by 2009 H1N1 influenza during pregnancy. *Chin Med J.* 2013;126:1999–2000.
142. Liu C, Sun W, Wang C, Liu F, Zhou M. Delivery during extracorporeal membrane oxygenation (ECMO) support of pregnant woman with severe respiratory distress syndrome caused by influenza: a case report and review of the literature. *J Matern Fetal Neonatal Med.* 2019;32:2570–2574.
143. Loizos S, Cirillo C, Trimlett R, Price S. A pheochromocytoma-induced takotsubo syndrome case treated by venoarterial extracorporeal membrane oxygenation. *Eur Heart J.* 2017;38(supplement 1):1431.
144. Lueck S, Sindermann J, Martens S, Scherer M. Mechanical circulatory support for patients with peripartum cardiomyopathy. *J Artif Organs.* 2016;19:305–309.
145. Lund LH, Grinnemo K-H, Svenarud P, van der Linden J, Eriksson MJ. Myocardial recovery in peri-partum cardiomyopathy after continuous flow left ventricular assist device. *J Cardiothorac Surg.* 2011;6:150.
146. Lysenko L, Zaleska-Dorobisz U, Blok R, Dumanski A, Zielinska M, Kustrzycki W, Durek G. A successful cesarean section in a pregnant woman with A (H1N1) influenza requiring ECMO support. *Kardiochirurgia Pol.* 2014;11:216–219.
147. Eiras Mariño MDM, Taboada Muñoz M, Otero Castro P, Adrio Nazar B, Reija López L, Agra Bermejo R. Venoarterial extracorporeal membrane oxygenation and ventricular assistance with impella CP in an amniotic fluid embolism. *Rev Esp Cardiol (Engl Ed).* 2019;72:679–680.
148. McDonald C, Laurie J, Janssens S, Zazulak C, Kotze P, Shekar K. Successful provision of inter-hospital extracorporeal cardiopulmonary resuscitation for acute post-partum pulmonary embolism. *Int J Obstet Anesth.* 2017;30:65–68.
149. McKechnie RS, Patel D, Eitzman DT, Rajagopalan S, Murthy TH. Spontaneous coronary artery dissection in a pregnant woman. *Obstet Gynecol.* 2001;98:899–902.
150. McNamee K, Dawood F. Severe H1N1 virus in pregnancy requiring extracorporeal membrane oxygenation and lobectomy. *Obstet Med.* 2010;3:156–157.
151. Mendes PV, Moura E, Barbosa EVS, Hirota AS, Scordamaglio PR, Aijar FM, Costa ELV, Azevedo LCP, Park M. Challenges in patients supported with extracorporeal membrane oxygenation in Brazil. *Clinics (Sao Paulo).* 2012;67:1511–1515.
152. Meng ML, Fu A, Westhoff C, Bacchetta M, Rosenzweig EB, Landau R, Smiley R. Eisenmenger syndrome in pregnancy: when is it time for ECMO?: a case report. *A A Pract.* 2018;11:11.
153. Miessau J, Yang Q, Unai S, Entwistle JW, Cavarocchi NC, Hirose H. Venovenous extracorporeal membrane oxygenation using a double-lumen bi-caval cannula for severe respiratory failure post total artificial heart implantation. *Perfusion.* 2015;30:410–414.
154. Mikami T, Kamiyama H. Emergent caesarean section under mechanical circulatory support for acute severe peripartum cardiomyopathy. *J Cardiol Cases.* 2018;17:200–203.

155. Mita K, Tsugita K, Yasuda Y, Matsuki Y, Obata Y, Matsuki Y, Kamisawa S, Shigemi K. A successfully treated case of cardiac arrest after caesarean section complicated by pheochromocytoma crisis and amniotic fluid embolism. *J Anesth*. 2017;31:140–143.
156. Morsolini M, Sciacca S, Panarello G, Martucci G, Bertani A, Longo R, Vitolo P, Arcadipane A, Pilato M. Delivery during ECMO: a single-center case series. *J Heart Lung Transplant*. 2017;36:S333–S334.
157. Nair P, Davies AR, Beca J, Bellomo R, Ellwood D, Forrest P, Jackson A, Pye R, Seppelt I, Sullivan E, et al. Extracorporeal membrane oxygenation for severe ARDS in pregnant and postpartum women during the 2009 H1N1 pandemic. *Intensive Care Med*. 2011;37:648–654.
158. Nair L, Oates M, Russell L, Smith I, Thomson B, Wall D, Fiene A. Critical pulmonary arterial hypertension necessitating bilateral lung transplantation. *Pulm Circ*. 2017;7:272.
159. Naqvi SY, Yoruk A, Pressman E, Olson-Chen C, Prasad S, Barrus B, Gosev I, Alexis J, Thomas S. Cardiomyopathy bridged to heart transplant with ambulatory extracorporeal membrane oxygenation in a peripartum patient. *J Am Coll Cardiol*. 2018;71:2418.
160. Neurath M, Benzing A, Knolle P, Grundmann H, Dippold W, Zumbuschfeld KHM. Acute respiratory-failure in falciparum-malaria during pregnancy—successful treatment using extracorporeal CO₂ elimination. *Dtsch Med Wochenschr*. 1993;118:1060–1066.
161. Ngatchou W, Ramadan AS, Van Nooten G, Antoine M. Left tilt position for easy extracorporeal membrane oxygenation cannula insertion in late pregnancy patients. *Interact Cardiovasc Thorac Surg*. 2012;15:285–287.
162. Noah MA, Dawrant M, Faulkner GM, Hill AM, Harvey C, Hussain A, Jenkins DR, Nichani S, Peek GJ, Sosnowski AW, et al. Panton-Valentine leukocidin expressing *Staphylococcus aureus* pneumonia managed with extracorporeal membrane oxygenation: experience and outcome. *Crit Care Med*. 2010;38:2250–2253.
163. O’Gara PT, Shepard JAO, Yared K, Sohani AR. Case 39-2009: a 28-year-old pregnant woman with acute cardiac failure. *N Engl J Med*. 2009;361:2462–2473+2404.
164. Pagel PS, Lilly RE, Nicolosi AC. Use of ECMO to temporize circulatory instability during severe Brugada electrical storm. *Ann Thorac Surg*. 2009;88:982–983.
165. Panarello G, Occhipinti G, Capitanio G, Ferrazza V, Vitolo P, Pilato M, Di Lorenzo G, Arcadipane AF. Treatment of A/H1N1 related severe ARDS by extracorporeal membrane oxygenation in pregnant and postpartum women, during the 2009 flu pandemic. Single center experience. *Intensive Care Med*. 2010;36(suppl 2):S235.
166. Panarello G, D’Ancona G, Capitanio G, Occhipinti G, Attardo G, Bertani A, Arcadipane A. Cesarean section during ECMO support. *Minerva Anesthesiol*. 2011;77:654–657.
167. Park SH, Chin JY, Choi MS, Choi JH, Choi YJ, Jung KT. Extracorporeal membrane oxygenation saved a mother and her son from fulminant peripartum cardiomyopathy. *J Obstet Gynaecol Res*. 2014;40:1940–1943.
168. Parkins MD, Fonseca K, Peets AD, Laupland KB, Shamseddin K, Gill MJ. A potentially preventable case of serious influenza infection in a pregnant patient. *Can Med Assoc J*. 2007;177:851–853.
169. Paruchuri Y, Hauspurg A, Donadee C, Sakamoto S, Murugan R. Can we achieve low tidal volume ventilation in pregnant women with acute respiratory distress syndrome? *Am J Obstet Gynecol*. 2018;218:S470–S471.
170. Patel S, Loveridge R, Willars C, Best T, Gelandt E, Morgan L, Butt S, Auzinger G. First for a child, now for a new mother: extending the reach of emergency liver transplantation by bridging with ECMO—a case report. *Eur J Heart Fail*. 2017;19:41–42.
171. Patroniti N, Zangrillo A, Pappalardo F, Peris A, Cianchi G, Braschi A, Iotti GA, Arcadipane A, Panarello G, Ranieri VM, et al. The Italian ECMO network experience during the 2009 influenza A (H1N1) pandemic: preparation for severe respiratory emergency outbreaks. *Intensive Care Med*. 2011;37:1447–1457.
172. Patrut GV, Neamtu C, Ionac M. Leg for life? The use of sartorius muscle flap for the treatment of an infected vascular reconstructions after VA-ECMO use. A case report. *Int J Surg Case Rep*. 2015;16:25–28.
173. Pechulis R, Miller C, Wu J, Pechulis M, Lindauer L. Extreme physical therapy-progression of functional mobility of 25 year old on ECMO 72 days. *Crit Care Med*. 2014;42:A1653.
174. Pekka H, Markku S, Kalervo W. Case report: ECMO as comprehensive treatment for high risk pulmonary embolism (PE). *Int J Artif Organs*. 2013;36:279.
175. Perdue SM, Poore BJ, Babu AN, Stribling WK. Successful use of extracorporeal membrane oxygenation support in severe septic shock with associated acute cardiomyopathy. *J Card Surg*. 2018;33:50–52.
176. Pereira GB, Barney J. Non-familial pulmonary alveolar proteinosis in a pregnancy complicated by stenotrophomonas maltophilia. *Am J Respir Crit Care Med*. 2018;197:A4790. MeetingAbstracts.
177. Pham T, Combes A, Roze H, Chevret S, Mercat M, Roch A, Mourvillier B, Ara-Somohano C, Bastien O, Zogheib E, et al. Extracorporeal membrane oxygenation for pandemic influenza A (H1N1)-induced acute respiratory distress syndrome: a cohort study and propensity-matched analysis. *Am J Respir Crit Care Med*. 2013;187:276–285.
178. Phillips MR, Klein M, Shah M, Charles AG. Venovenous extracorporeal membrane oxygenation in pregnancy: does foetal viability matter? *Anaesth Intensive Care*. 2017;45:524–525.
179. Piatrovich NS, Shestakova LG, Ostrovsky YP. Successful application of extracorporeal membrane oxygenation in woman after childbirth. *Eur J Heart Fail*. 2018;20(supplement 1):174.
180. Pirsaheli R, Wijman C, Hobbs K, Snider R. Survival of a patient with propofol infusion syndrome and prolonged asystole using ECMO. *Neurocrit Care*. 2012;17(suppl 2):S185.
181. Plotkin JS, Shah JB, Lofland GK, DeWolf AM. Extracorporeal membrane oxygenation in the successful treatment of traumatic adult respiratory distress syndrome: case report and review. *J Trauma*. 1994;37:127–130.
182. Power CA, Van Heerden PV, Moxon D, Martindale G, Roberts B. Extracorporeal membrane oxygenation for critically ill patients with influenza A (H1N1) 2009: a case series. *Crit Care Resusc*. 2011;13:38–43.
183. Prakash S, Bihari S, Wiersema U. A rare case of rapidly enlarging tracheal lobular capillary hemangioma presenting as difficult to ventilate acute asthma during pregnancy. *BMC Pulm Med*. 2014;14:41.
184. Rabin J, Kon Z, Garcia J, Griffith B, Herr D. Successful bridge to transplant after 155 days of V-V ECMO. *Crit Care Med*. 2012;40:292.
185. Rademacher W, Lauten A, Lauten A, Ragoschke-Schumm A, Figulla HR. Postpartum unmasking of a severe triple-vessel-disease with acute myocardial infarction. *Clin Res Cardiol*. 2010;99:463–466.
186. Radsel P, Gorjup V, Jazbec A, Knafejl R, Lucovnik M, Kavsek G, Kornhauser Cerar L, Noc M. Pregnancy complicated by influenza A ARDS requiring consecutive VV-ECMO treatment with successful vaginal delivery. *J Artif Organs*. 2018;17:17.
187. Raley M, Gill B, Grier L, Conrad S. Arteriovenous CO₂ removal (AVCO2R) in a postpartum patient with refractory status asthmaticus. *Crit Care Med*. 2015;43:316.
188. Ramirez RL, Zarafshar S. A heartbreaking tale: a young pregnant woman presents with acute cardiomyopathy and a surprising cause. *J Gen Intern Med*. 2018;33:426.
189. Rein JL, Etra AM, Patel JJ, Stein JL, Rivers AL, Gershengorn HB, Awerbuch E, Kreiswirth BN, Koshy SC. Death of woman with peripartum influenza B virus infection and necrotizing pneumonia. *Emerg Infect Dis*. 2014;20:1259–1260.
190. Reyftmann L, Morau E, Dechaud H, Frapier JM, Hedon B. Extracorporeal membrane oxygenation therapy for circulatory arrest due to postpartum hemorrhage. *Obstet Gynecol*. 2006;107:511–514.
191. Riddell J IV, Chenoweth CE, Kauffman CA. Disseminated *Scedosporium apiospermum* infection in a previously healthy woman with HELLP syndrome. *Mycoses*. 2004;47:442–446.
192. Riestler A, Weismann D, Quinkler M, Lichtenauer UD, Sommerey S, Halbritter R, Penning R, Spitzweg C, Schopohl J, Beuschlein F, et al. Life-threatening events in patients with pheochromocytoma. *Eur J Endocrinol*. 2015;173:757–764.
193. Robbins T, Kanu C, Lam SJ, Zammit-Mangion M. Extracorporeal membrane oxygenation in the treatment of an infective exacerbation of asthma in pregnancy. *BJOG*. 2015;122:42.
194. Robertson LC, Allen SH, Konamme SP, Chestnut J, Wilson P. The successful use of extra-corporeal membrane oxygenation in the management of a pregnant woman with severe H1N1 2009 influenza complicated by pneumonitis and adult respiratory distress syndrome. *Int J Obstet Anesth*. 2010;19:443–447.
195. Rodriguez Chaverri A, Ponz De Antonio I, Garcia-Cosio MD, Moran Fernandez L, De Juan Baguda J, Arribas Ynsaurraga F, Delgado Jimenez JF. A case of advanced heart failure: when not everything is as it seems. *Eur J Heart Fail*. 2018;20(supplement 1):21.
196. Roncon-Albuquerque R, Basilio C, Figueiredo P, Silva S, Mergulhao P, Alves C, Veiga R, Castelo-Branco S, Paiva L, Santos L, et al. Portable miniaturized extracorporeal membrane oxygenation systems for

- H1N1-related severe acute respiratory distress syndrome: a case series. *J Crit Care*. 2012;27:454–463.
197. Rubin E, Minkin R, Khoulil H. Successful use of extracorporeal membrane oxygenation (ECMO) to treat pulmonary thromboembolism and amniotic fluid embolism in a postpartum patient. *Am J Respir Crit Care Med*. 2013;187:A4431.
 198. Sakamoto C, Miyashita S, Ochiai S, Motegi E, Kuno T, Tada K, Fukasawa I. Perimortem cesarean section (PMCS)-successful maternal resuscitation of out-hospital onset cardiopulmonary arrest, a case report. *J Obstet Gynaecol Res*. 2018;44:1568.
 199. Sakanashi Y, Terasaki H, Tajiri A, Mizoguchi S, Chung IS, Okamoto K, Morioka T. A case of Eisenmenger's syndrome treated with extracorporeal lung and heart assist in the postpartum period. *J Anesth*. 1994;8:107–109.
 200. Salazar LA, Schreuder CM, Eslava JA, Murcia AS, Forero MJ, Orozco-Levi MA, Echeverria LE, Figueredo AI. Extracorporeal membrane oxygenation in dengue, malaria, and acute Chagas disease. *ASAIO J*. 2017;63:e71–e76.
 201. Satoh H, Masuda Y, Izuta S, Yaku H, Obara H. Pregnant patient with primary pulmonary hypertension: general anesthesia and extracorporeal membrane oxygenation support for termination of pregnancy. *Anesthesiology*. 2002;97:1638–1640.
 202. Scherrer V, Lasgi C, Hariri S, Dureuil B, Savoure A, Tamion F, Doguet F. Radiofrequency ablation under extracorporeal membrane oxygenation for atrial tachycardia in postpartum. *J Card Surg*. 2012;27:647–649.
 203. Scriven J, McEwen R, Mistry S, Green C, Osman H, Bailey M, Ellis C. Swine flu: a Birmingham experience. *Clin Med*. 2009;9:534–538.
 204. Seczynska B, Jankowski M, Nowak I, Szczeklik W, Szuldrzynski K, Krolkowski W. Pregnancy-related H1N1 influenza and severe acute respiratory distress syndrome successfully treated with extracorporeal membrane oxygenation despite difficult vascular access. *Pol Arch Med Wewn*. 2014;124:136–137.
 205. Seidler D, Franklin M. Metastatic choriocarcinoma to the lung: changing dogma. *Chest*. 2016;150:765A.
 206. Sellami W, Hajje Z, Ferjani M. Fulminant acute myocarditis in a pregnant woman treated with circulatory assistance. *Resuscitation*. 2017;26:523–527.
 207. Seong GM, Kim SW, Kang HS, Kang HW. Successful extracorporeal cardiopulmonary resuscitation in a postpartum patient with amniotic fluid embolism. *J Thorac Dis*. 2018;10:E189–E193.
 208. Seth B, Gonzalez M, Schembri F. Status asthmaticus in pregnancy requiring sevoflurane and ECMO. *Am J Respir Crit Care Med*. 2018;197:A5242. Meeting Abstracts.
 209. Shah N, Perrin F. Extracorporeal membrane oxygenation (ECMO) in cystic fibrosis. *Paediatr Respir Rev*. 2014;15(suppl 1):26–28.
 210. Shamsah M, Alfoudri H. Extracorporeal membrane oxygenation for cardiac arrest in pregnancy secondary to severe pulmonary hypertension. *International Journal of Obstetric Anesthesia*. 2017;31(supplement 1):S59.
 211. Shen HP, Chang WC, Yeh LS, Ho M. Amniotic fluid embolism treated with emergency extracorporeal membrane oxygenation: a case report. *J Reprod Med*. 2009;54:706–708.
 212. Shuang L, Yang C, Li Z, Lin S, Li Z, Zhou J, Mai Y. Clinical analysis of the first maternal patient infected with novel avian influenza A (H5N6) virus in the world. *Zhonghua Wei Zhong Bing Ji Jiu Yi Xue*. 2016;28:988–993.
 213. Sim SS, Chou HC, Chen JW, Ma MH. Extracorporeal membrane oxygenation in maternal arrhythmic cardiogenic shock. *Am J Emerg Med*. 2012;30:1012.e3–5.
 214. Skolnik S, Ioscovich A, Eidelman LA, Davis A, Shmueli A, Aviram A, Orbach-Zinger S. Anesthetic management of amniotic fluid embolism—a multi-center, retrospective, cohort study. *J Matern Fetal Neonatal Med*. 2019;32:1262–1266.
 215. Smiechowicz J, Barteczko B, Grotowska M, Kaiser T, Zielinski S, Kubler A. [Severe acute respiratory distress syndrome complicating type A (H1N1) influenza treated with extracorporeal CO₂ removal]. *Anestezjol Intens Ter*. 2011;43:98–103.
 216. Smith IJ, Gillham MJ. Fulminant peripartum cardiomyopathy rescue with extracorporeal membranous oxygenation. *Int J Obstet Anesth*. 2009;18:186–188.
 217. Stankiewicz A, Frank M, Dmitruk I, Czudzinowicz K, Teodorowski W, Walicka-Pylko A, Matulewicz-Gilewicz J, Bernacki A, Juszczak G, Matlak K, et al. Effective therapy of influenza A/H1N1 acute respiratory distress syndrome using extracorporeal membrane oxygenation. *Kardiocir Torakochirurgia Pol*. 2011;8:462–464.
 218. Steinack C, Lenherr R, Hendra H, Franzen D. The use of life-saving extracorporeal membrane oxygenation (ECMO) for pregnant woman with status asthmaticus. *J Asthma*. 2017;54:84–88.
 219. Strecker T, Munch F, Weyand M. One hundred ten days of extracorporeal membrane oxygenation in a young woman with postpartum cerebral venous thrombosis and acute respiratory distress syndrome. *Heart Surg Forum*. 2012;15:180–E181.
 220. Su TW, Tseng YH, Wu TI, Lin PJ, Wu MY. Extracorporeal life support in adults with hemodynamic collapse from fulminant cardiomyopathies: the chance of bridging to recovery. *ASAIO J*. 2014;60:664–669.
 221. Takacs ME, Damisch KE. Extracorporeal life support as salvage therapy for massive pulmonary embolus and cardiac arrest in pregnancy. *J Emerg Med*. 2018;55:121–124.
 222. Takeda S, Kotani T, Nakagawa S, Ichiba S, Aokage T, Ochiai R, Taenaka N, Kawamae K, Nishimura M, Ujike Y, et al. Extracorporeal membrane oxygenation for 2009 influenza A (H1N1) severe respiratory failure in Japan. *J Anesth*. 2012;26:650–657.
 223. Tampo A, Yamaki M, Kawata D, Suzuki A, Akasaka N, Fujita S. A severe case of postpartum cardiomyopathy required veno-atrial extracorporeal membrane oxygenation. *Eur J Anaesthesiol*. 2014;31(suppl 52):178.
 224. Theodorou M, Gilbert E. Extracorporeal membrane oxygenation in a case of refractory status asthmaticus in pregnancy. *Chest*. 2015;148;(4_MeetingAbstracts):279A.
 225. Tincrès F, Conil JM, Crognier L, Rouget A, Georges B, Ruiz S. Veno-arterial extracorporeal membrane oxygenation in a case of amniotic fluid embolism with coexisting hemorrhagic shock: lessons learned. *Int J Obstet Anesth*. 2018;33:99–100.
 226. Ull C, Schildhauer TA, Strauch JT, Mugge A, Swol J. Veno-venous ECMO as a safe bridge to recovery in a patient with severe peripartum cardiomyopathy—learning from errors. *Perfusion*. 2017;32:328–332.
 227. Unterberg M, Nowak H, Gottschalk A. [Hypercapnic raised intracerebral pressure—ECMO therapy despite major intracerebral haemorrhage]. *Anesthesiol Intensivmed Notfallmed Schmerzther*. 2017;52:376–381.
 228. Uribarri A, Cruz-Gonzalez I, Dalmau MJ, Rubia-Martin MC, Ochoa M, Sanchez PL. Interhospital transfer in patients on ECMO support. An essential tool for a critical care network. *Rev Esp Cardiol*. 2017;70:1147–1149.
 229. van Zwet CJ, Rist A, Haeussler A, Graves K, Zollinger A, Blumenthal S. Extracorporeal membrane oxygenation for treatment of acute inverted takotsubo-like cardiomyopathy from hemorrhagic pheochromocytoma in late pregnancy. *A A Case Rep*. 2016;7:196–199.
 230. Veld Van Wingerden AWN, Maas J, Harinck HIJ, Mauritz R. Long-term extracorporeal membrane oxygenation in acute respiratory distress syndrome. *Neth J Crit Care*. 2015;19:20–24.
 231. Verroust N, Zegdi R, Ciobotaru V, Tsatsaris V, Goffinet F, Fabiani J-N, Mignon A. Ventricular fibrillation during termination of pregnancy. *Lancet*. 2007;369:1900.
 232. Visveswaran GK, Gidea C, Baran D, Cohen M, Zucker MJ. Acute left ventricular dysfunction complicating pregnancy on ECMO: triiodothyronine to the rescue with real time transesophageal echocardiography. *J Cardiol Cases*. 2016;13:33–36.
 233. Vitulo P, Beretta M, Martucci G, Hernandez Baravoglia CM, Romano G, Bertani A, Martino L, Callari A, Panarello G, Pilato M, et al. Challenge of pregnancy in patients with pre-capillary pulmonary hypertension: veno-arterial extracorporeal membrane oxygenation as an innovative support for delivery. *J Cardiothorac Vasc Anesth*. 2017;31:2152–2155.
 234. Wall CJ, Santamaria J. Extracorporeal membrane oxygenation: an unusual cause of acute limb compartment syndrome. *Anaesth Intensive Care*. 2010;38:560–562.
 235. Wang G, Zhou Y, Gong S, Dong H, Wu G, Xiang X, Tang J. A pregnant woman with avian influenza A (H7N9) virus pneumonia and ARDS managed with extracorporeal membrane oxygenation. *Southeast Asian J Trop Med Public Health*. 2015;46:444–448.
 236. Wei J, Yang HS, Tsai SK, Hsiung MC, Chang CY, Ou CH, Chang YC, Lee KC, Sue SH, Chou YP. Emergent bedside real-time three-dimensional transesophageal echocardiography in a patient with cardiac arrest following a caesarean section. *Eur J Echocardiogr*. 2011;12:E16.
 237. Weinberg L, Kay C, Liskaser F, Jones D, Tay S, Jaffe S, Seevanayagam S, Doolan L. Successful treatment of peripartum massive pulmonary embolism with extracorporeal membrane oxygenation and catheter-directed pulmonary thrombolytic therapy. *Anaesth Intensive Care*. 2011;39:486–491.

-
238. Welch SA, Snowden LN, Buscher H. Pandemic (H1N1) 2009 influenza, pregnancy and extracorporeal membrane oxygenation. *Med J Aust.* 2010;192:668.
 239. Wertaschnigg D, Lucovnik M, Moertl MG. Differences between venovenous and venoarterial extracorporeal membrane oxygenation in pregnancies. *Ann Thorac Surg.* 2017;103:361.
 240. Weyrich J, Bogdanski R, Ortiz JU, Kuschel B, Schneider KT, Lobmaier SM. Interdisciplinary peripartum management of acute respiratory distress syndrome with extracorporeal membrane oxygenation—a case report and literature review. *Geburtshilfe Frauenheilkd.* 2016;76:273–276.
 241. Williams J, Kim A, Bartlett R, Mychaliska G, Chames M. Life-threatening cardiopulmonary failure in pregnancy and the peripartum period: is extracorporeal life support effective? *Am J Obstet Gynecol.* 2008;199:S152.
 242. Wise EM, Harika R, Zahir F. Successful recovery after amniotic fluid embolism in a patient undergoing vacuum-assisted vaginal delivery. *J Clin Anesth.* 2016;34:557–561.
 243. Yang HS, Hong YS, Rim SJ, Yu SH. Extracorporeal membrane oxygenation in a patient with peripartum cardiomyopathy. *Ann Thorac Surg.* 2007;84:262–264.
 244. Yang YP, Lin LS. A pregnant woman with acute massive pulmonary embolism. *Acta Cardiol.* 2014;30:82–85.
 245. Yeh TC, Liu CP, Tseng CJ, Liou JC. Postpartum patient with congenital patent ductus arteriosus mimicking acute pulmonary embolism. *BMJ Case Rep.* 2013;22:22.
 246. Young S, Pritzker M, Rosenberg M. Vacuum-assisted thrombectomy of massive pulmonary embolism. *J Vasc Interv Radiol.* 2016;27:1094–1096.
 247. Zhang J, Lu J, Zhou X, Xu X, Ye Q, Ou Q, Li Y, Huang J. Perioperative management of pregnant women with idiopathic pulmonary arterial hypertension: an observational case series study from China. *J Cardiothorac Vasc Anesth.* 2018;07:07.
 248. Zhang JL, Lu JK, Zhou XR, Xu XF, Ye Q, Ou QT, Li YN, Huang JP. Perioperative management of pregnant women with idiopathic pulmonary arterial hypertension: an observational case series study from China. *J Cardiothorac Vasc Anesth.* 2018;32:2547–2559.
 249. Zingel D, Avsar M, Schmitto JD, Malehsa D, Haverich A, Strueber M. Left ventricular assist device implantation via mini-sternotomy in a case of peripartum cardiomyopathy. *Artif Organs.* 2012;36:A43.
 250. Zykova I, Švančar P, Pratingerová J, Sedlák P, Krejzar Z, Remeta P, Škantárová J, Žihlová L, Morman D. Analysis of the impact of pandemic influenza 2009 a H1N1 outbreak on intensive care in a tertiary care hospital. *Intensive Care Med.* 2010;36(suppl 2):S284.

SUPPLEMENTAL MATERIAL

Data S1.

Full search terms

ECMO in pregnancy searches

Ovid MEDLINE search for the sentinel articles

("23268668" or "23942727" or "22922930" or "28719429" or "28195885" or "25819202" or "29739630" or "27056763" or "26758056" or "27881700" or "26942349" or "25248040" or "19019293" or "26307595" or "26825433").ui.

Ovid MEDLINE; Ovid MEDLINE In-Process & Other Non-Indexed Citations; Ovid MEDLINE Epub Ahead of Print (800 results on September 11, 2018)

(exp pregnancy/ or exp pregnancy complications/ or exp obstetric surgical procedures/ or exp maternal health services/ or postpartum period/ or (c-section* or caesarean* or cesarean* or childbirth* or labor or labors or labour* or maternal or mother* or obstetric* or peri-partum or peripartum or post-natal or postnatal or postpartum or postpartum or pregnan* or pre-natal or prenatal).tw.) and (exp extracorporeal membrane oxygenation/ or (ecmo or extra-corporeal or extracorporeal).tw.) not ((exp adolescent/ or exp child/ or exp infant/) not exp adult/)

Elsevier Embase.com (963 results on September 11, 2018)

('maternal care'/exp OR 'obstetric operation'/exp OR 'obstetrics'/exp OR 'perinatal care'/exp OR 'perinatal period'/de OR 'pregnancy'/exp OR 'pregnancy disorder'/exp OR 'prenatal care'/exp OR 'prenatal period'/de OR caesarean*:ab,ti OR 'c-section':ab,ti OR 'c-sections':ab,ti OR cesarean*:ab,ti OR childbirth*:ab,ti OR labor:ti OR labors:ti OR labours*:ti OR maternal:ab,ti OR mother*:ab,ti OR obstetric*:ab,ti OR 'peri-partum':ab,ti OR peripartum:ab,ti OR 'post-natal':ab,ti OR postnatal:ab,ti OR 'post-partum':ab,ti OR postpartum:ab,ti OR pregnan*:ab,ti OR 'pre-natal':ab,ti OR prenatal:ab,ti) AND ('extracorporeal oxygenation'/exp OR ecmo:ab,ti OR (((extracorporeal OR 'extra-corporeal') NEAR/3 (support OR membrane OR oxygenation)):ab,ti) NOT ('juvenile'/exp NOT 'adult'/exp)

Clarivate Web of Science (992 results on September 11, 2018)

TS=(ECMO OR extracorporeal OR "extra-corporeal") AND TS=("c-section" OR "c-sections" OR caesarean* OR cesarean* OR childbirth* OR labor OR labors OR labour* OR maternal OR mother* OR obstetric* OR peripartum OR "peri-partum" OR "post-natal" OR postnatal OR postpartum OR "post-partum" OR pregnan* OR "pre-natal" OR prenatal)

EBSCOhost CINAHL (325 results on September 11, 2018)

(MH "Extracorporeal Membrane Oxygenation" OR TI (ECMO OR extracorporeal OR "extra-corporeal") OR AB (ECMO OR extracorporeal OR "extra-corporeal")) AND (MH ("pregnancy+" OR "pregnancy complications+" OR "pregnancy outcomes+") OR TI ("c-section" OR "c-sections" OR caesarean* OR cesarean* OR childbirth* OR labor OR labors OR labour* OR maternal OR mother* OR obstetric* OR peripartum OR "peri-partum" OR "post-natal" OR postnatal OR postpartum OR "post-partum" OR pregnan* OR "pre-natal" OR prenatal) OR AB ("c-section" OR "c-sections" OR caesarean* OR cesarean* OR childbirth* OR labor OR labors OR labour* OR maternal OR mother* OR obstetric* OR peripartum OR "peri-partum" OR "post-natal" OR postnatal OR postpartum OR "post-partum" OR pregnan* OR "pre-natal" OR prenatal))

Table S1. Breakdown of all cases (n = 358).

Study (Author, Year)	Type of Study	Delivery Type	Indication	Disease Process/Indication	ECLS Type	ECLS Duration (days)	Maternal Complications	Maternal Mortality	Fetal Complications	Fetal Mortality
³⁴ Abbal 2014	Case report	C/S	ARDS	31 year old G2P1 at 22 weeks with ARDS due to H1N1, 3 days after delivery underwent ECLS	VV	13	None	No	Preterm delivery at 24 weeks, NICU admission	Yes
³⁵ Abid Memon 2018	Case report	C/S	PAH, cardiac arrest	20 year old at 26 weeks with PAH, Von Willebrand's, worsening PAH, post-delivery PEA s/p CPR onto VA	VA	24	Pericardial effusions, pericardial window, hemoptysis requiring bronchoscopy and cauterization, trach	No	Preterm delivery at 26 weeks, NICU	No
³⁶ Agerstrand 2016	Single center retrospective review (Columbia)	N/A	ARDS (17), cardiac arrest (3), PE (2), AFE (2), PAH (1)	ARDS in 17 (flu 6, PNA 2, aspiration 3, TRALI 6, non-pulmonary sepsis 2), ECPR in 3, PE in 2, AFE in 2, PAH in 1; Antepartum in 4 patients, Postpartum in 14	VV in 14, VA in 1, VAV in 3	Median 6 days	ECMO related bleeding complications in 6 (DIC), 4/13 c/s cases had intraabdominal bleeding, 1 limb ischemia resulting in BKA, cannula associated DVT in 5	2/18	1 miscarriage after cannulation at 18 weeks, 2 miscarriages prior to ECMO cannulation; median GA 32 weeks	4/18
³⁶ Agerstrand 2016	Single center retrospective review (Columbia)	C/S	PAH	Patient at 34 and 6/7 weeks with PAH requiring VV support then septic shock requiring VA, antepartum 3 days	VV then VA	24	DIC, abdominal compartment syndrome, VV 12d then VA for 12d	N/A	N/A	N/A
³⁶ Agerstrand 2016	Single center retrospective review (Columbia)	C/S	ARDS	Patient at 28 and 5/7 weeks with H1N1 ARDS, antepartum 16 days	VV		Preeclampsia, DIC, bleeding	N/A	N/A	N/A

³⁶ Agerstrand 2016	Single center retrospective review (Columbia)	C/S	ARDS	Patient at 26 and 3/7 weeks with H1N1 ARDS developed renal failure, septic shock, delivered on ECMO c/s, preeclampsia, DIC, multisite bleeding	VV		Renal failure and septic shock, delivered on ECMO c/s, preeclampsia, DIC, multisite bleeding	No	N/A	N/A
³⁶ Agerstrand 2016	Single center retrospective review (Columbia)	C/S	ARDS	Patient at 32 weeks with ARDS due to urosepsis, antepartum 7 days	VV	6	N/A	N/A	N/A	N/A
³⁷ Alamo 1995	Case series	VD	PPH, ARDS	28 year old at 32 weeks with hypertension c/b fetal distress, forceps delivery, PPH, DIC, preeclampsia and ARDS	VV	2	Renal failure, septic shock acinetobacter, died 7 days after decannulation	Yes	N/A	N/A
³⁷ Alamo 1995	Case series	C/S	ARDS	19 year at 37 weeks with hypertension, 3 weeks post-delivery necrotic pancreatitis, DIC, multiorgan failure, ARDS	VV	0.70833	DIC, renal failure, intracranial hematoma	Yes	N/A	N/A
³⁸ Alyamani 2018	Case report	C/S	ARDS	38 year old G9P8 at 30 and 3/7 weeks with sarcoidosis with ARDS, alveolar hemorrhage, cannulated antepartum	VV	14	Profuse bleeding after bronchoscopy, DVT after decannulation	No	Preterm delivery at 31 weeks, NICU	No
³⁹ Amancio 2017	Case report	C/S	ARDS	30 year old G1P0 at 27 weeks with H1N1 ARDS with hypoxemic respiratory failure cannulated antepartum	VV	9	Enterobacter PNA	No	None	No
⁹ Anselmi 2015	Case report and systematic review	C/S	ARDS	32 year old G1P0 at 28 weeks with influenza ARDS	VV	12	Transient maternal peroneal nerve paralysis, C/S after decannulation	No	None	No

40Arlt 2009	Case report	C/S	PE, cardiac arrest	27 year old with massive PE with PEA, given tPA, ECMO transported with hand-held system, underwent emergent hysterectomy and pulmonary thrombectomy under ECMO and remained on ECMO 4 days postop	VA	4	Vaginal and endotracheal bleeding after thrombolysis, emergency hysterectomy	No	N/A	No
41Barbalic 2016	Case report	D&E	PPH, ARDS	39 year old at 21 weeks with PPROM with miscarriage, D&E with PPH, atony, hysterectomy subsequent DIC, ARDS, hemodynamic instability, hypoxemia	N/A	8	Intraabdominal hemorrhage requiring multiple laparotomies and evacuations, hemolytic anemia	No	IUFD prior to ECLS	N/A
42Barnes 2018	Case report	C/S	ILD	24 year old at 31 weeks with RA associated ILD with pulmonary vasculitis with emergent C/S requiring ECMO	N/A	6	Multiple infections, colitis, PNA, cardiac arrest in setting of refractory hypoxemia 56 days after ECLS	Yes	Preterm delivery at 31 weeks, NICU	No
43Bartlett 1974	Case series	VD	AFE, cardiac failure	29 year old at 31 weeks with IUFD IOL c/b AFE and DIC	VA	12	PNA with gram negative septicemia, necrotizing pneumonitis	Yes	IUFD prior to ECLS	N/A
44Bataillard 2016	Case series	C/S	PE	35 year old at 27 weeks with acute PE with RV dilation, hemodynamic instability and hypoxia	VA	10	Groin wound infection	No	Preterm delivery at 31 weeks, NICU	No
44Bataillard 2016	Case series	N/A	PE, cardiac arrest	26 year old at 10 weeks with PE with cardiac arrest requiring resuscitation - later delivered a healthy baby at 37 weeks	VA	4	Groin wound infection treated with antibiotics, R external iliac thrombus	No	N/A	No
45Bautista 2018	Case report	C/S	PAH, cardiac failure	18 year old at 24 weeks with pulmonary hypertension due to chronic venoocclusive disease	VV	10	Worsening after VV ECMO decannulation, lung transplant rejected, hemodynamic	Yes	IUFD at 24 hours	Yes

							and respiratory failure			
⁴⁶Bellissima 2011	Case series	N/A	ARDS	31 year old pregnant patient with H1N1 with ARDS	N/A		H1N1 with ARDS	No	N/A	N/A
⁴⁷Benetis 2016	Case report	C/S	Septic shock, ARDS	18 year old G1P0 at 26 weeks with sepsis due to endometritis from staph aureus and enterobacter, C/S at 26 weeks c/b DIC, pulmonary edema, hemodynamic instability then hysterectomy developed ARDS, cannulated on PPD# 4	VA	22	Bleeding at cannulation site, hematoma infection, hemothorax, repeat thoracotomies, sepsis, subclavian artery rupture, R hand numbness	No	Preterm delivery at 27 weeks, NICU	No
⁴⁸Besnier 2013	Case report	C/S	PPCM, cardiac arrest, Takotsubo	32 year old at 38 weeks for urgent C/S for prolapsed cord under general anesthesia, VT then cardiac arrest s/p shock LV failure (EF 17%) requiring ECMO, Takotsubo	VA	7	Bleeding requiring surgical evacuation	No	N/A	N/A
⁴⁹Beurther et 2013	Prospective study ECMO rescue team	N/A	PPCM	3 patients report with PPCM	VA		N/A	2/3	N/A	N/A
⁵⁰Biderman 2017	Retrospective review	VD	Cardiac failure	36 year old with toxic shock due to GAS on PPD# 4	VA	8.5	DIC	No	N/A	No
⁵⁰Biderman 2017	Retrospective review	C/S	AFE	41 year old with AFE	VA	4	DIC, tracheotomy	No	N/A	No
⁵⁰Biderman 2017	Retrospective review	C/S	AFE	41 year old with AFE	VA	6	DIC, tracheotomy	No	N/A	No
⁵⁰Biderman 2017	Retrospective review	VD	ARDS	37 year old at 13 weeks with ARDS due to H1N1	VA then VV	16	DIC, tracheotomy; VA 7 d then VV for 9	Yes	SAB	Yes
⁵⁰Biderman 2017	Retrospective review	C/S	Cardiac failure	30 year old at 33 weeks with infectious PNA	VA	32	Tracheotomy	Yes	N/A	No

⁵⁰ Biderman 2017	Retrospective review	VD	Septic shock, ARDS	30 year old at 20 weeks with infectious PNA (h flu)	VA	3	Tracheotomy	No	Died 3 days into ECLS	Yes
⁵⁰ Biderman 2017	Retrospective review	C/S	Septic shock, ARDS	19 year old with septic shock ARDS diffuse peritonitis PPD# 2	VA	11	Tracheotomy	No	N/A	No
⁵⁰ Biderman 2017	Retrospective review	C/S	Septic shock, ARDS	22 year old with infectious PNA PPD# 7	VA	20	Tracheotomy	Yes	N/A	No
⁵⁰ Biderman 2017	Retrospective review	VD	Cardiac failure, heart disease	38 year old with critical MS c/b cardiogenic shock, LV failure, pulmonary edema on PPD# 1	VA	20	N/A	No	TAB at 12 weeks prior to ECLS	Not counted as mortality
⁵⁰ Biderman 2017	Retrospective review	VD	Cardiac failure	40 year old with cardiogenic shock, LV failure on PPD# 5	VA	6	N/A	No	N/A	No
⁵⁰ Biderman 2017	Retrospective review	C/S	AFE	31 year old woman with AFE	VA	0	Death	Yes	N/A	No
⁵¹ Bok 2014	Case report	VD	ARDS	44 year old at 23 weeks with cryptogenic organizing PNA, VV ECMO then listed for lung transplant, stillbirth at 23 weeks	VV	13	Waited for lung transplant	No	SAB at 23 weeks	Yes
⁵² Bouabdallaoui 2017	Case series	VD (7) C/S (3)	PPCM	10 patients at average GA at 38 weeks with PPCM	VA	Peripheral support (all fem-fem) median 3 days, Central support 51 days	Pulmonary edema (2), bleeding at cannulation site (1), limb ischemia (1) and infection at cannulation site c/b septic shock (1), on dialysis before ECMO in 30%	5/10	N/A	N/A
⁵³ Bowkalo w 2011	Case report	VD	ARDS	24 year old G4P2 at 20 and 6/7 weeks with H1N1 ARDS	N/A	28	Died	Yes	SAB at 21 weeks	Yes
⁵⁴ Bruch 2013	Case report	VD	PE, cardiac arrest	31 year old G1P0 at 19 weeks PE circulatory shock requiring CPR, ECLS and thrombectomy, stillbirth at 19 weeks requiring D&C	VA	5	Bleeding requiring transfusions	No	SAB on ECMO	Yes

⁵⁵ Cerene 1977	Case report	VD	Aspiration pneumonitis, ARDS	32 year old with ARDS due to gastric aspiration during forceps delivery c/b cardiovascular collapse	VA	4.95833	Mild bleeding at insertion site	No	N/A	N/A
⁵⁶ Chambers 2018	Case report	N/A	Sickle cell crisis	20 year old G1P0 at 25 and 3/7 weeks with sickle cell with acute chest syndrome, cannulated postpartum	VV		Blood transfusions	No	Preterm delivery	No
⁵⁷ Champion 2017	Case report	C/S	PPCM	30 year old at 34 weeks with TTP c/b HELLP and sepsis with salmonella, PPCM day on PPD# 4	VA	18	Renal failure, discharged after 45 days	No	Preterm delivery at 34 weeks	No
⁵⁸ Chao 2016	Case series	VD	ARDS	35 year old G1P0 at 16 weeks with viral PNA with hypoxemic respiratory failure	VV	9		No	SAB at 16 weeks	Yes
⁵⁸ Chao 2016	Case series	C/S	PPCM	29 year old G1P0 at 34 weeks with PPCM s/p C/S sent home on diuretics and digoxin but returned 1 month later requiring mechanical ventilation and pressors so put on ECMO found to have EF 18%	VA	8.5		No	Preterm delivery at 34 weeks	No
⁵⁹ Chehab 2015	Case report	C/S	PPCM	23 year old at 35 weeks with PPCM EF<15% within 1 week of delivery	VA		Major hemorrhage, multiorgan failure, hemothorax, cannula dislodgement	Yes	Preterm delivery at 35 weeks	N/A
⁶⁰ Chillcott 1995	Case report	VD	ARDS, sepsis	20 year old G1P0 at 26 weeks with staph aureus septicemia, hypoxemia, ARDS underwent extracorporeal CO ₂ removal on PPD# 16	ECCO ₂ (VV)	47	Impaired skin integrity, pulmonary bleeding, HSV PNA, trach, hyperbilirubinemia, proteus and enterobacter PNA, oxygenator changes	No	Preterm delivery at 26 weeks, NICU, IVH	No

⁶¹Cho 2006	Case report	C/S	PAH, cardiac failure	24 year old at 38 weeks with PAH c/b RV failure post-C/S and aberrant pulmonary artery on PPD# 4	VV	33	HIT, thrombocytopenia, required IVIG, massive pulmonary hemorrhage, discovered to have aberrant right PA	No	N/A	No
⁶²Choi 2016	Case report in commentary	C/S	Cardiac arrest	26 year old G1P0 at 30 weeks with HELLP c/b IUFD s/p c/s c/b seizure followed by cardiac arrest/CPR	VA		Hemolysis, need for blood transfusion, dialysis, discharged 1 month post arrest	No	Pre-ECMO fetal demise	Not counted as mortality
⁶³Chuang 2015	Case report	C/S	PE, cardiac arrest	29 year old G1P1 with PE s/p PEA and CPR underwent PTE 2 days after admission on PPD# 2	VA	2	Burn injuries from resuscitation in ED, staph and influenza infections, discharged day 43	No	N/A	N/A
⁶⁴Clark 1991	Case series	N/A	ARDS	33 year old at 12 weeks with varicella PNA c/b ARDS	VV	3.75	Blood transfusions	No	TAB at 15 weeks due to concern for fetal anomalies incurred from ECLS	Yes
⁶⁵Clifford 2018	Case report	C/S	Asthma	33 year old G3P1 at 23 and 1/7 weeks with status asthmaticus, and possible PA clot on TTE	VV	6	VAP with moraxella and MSSA, influenza A	No	IUGR	No
⁶⁶Coscia 2012	Case series	VD	ARDS, malignancy	31 year old at 24 weeks with recent M3 AML hypoxemic respiratory failure c/b ARDS, spontaneously delivered 48 hours into iLA	iLA (VV)	8	Died 53 days after admission from AML complications	No	Unclear outcome, spontaneous preterm delivery at 24 weeks, NICU admission	N/A
⁶⁷Courouble 2011	Case report	VD	ARDS	21 year old G2P0 at 23 weeks with H1N1 ARDS	VV	9	Multiple transfusions, epistaxis during ECMO run, staph bacteremia after decannulation	No	None	No

⁶⁸Crawford 2015	Case report	C/S	ARDS	37 year old G1P0 at 21 weeks with influenza A ARDS c/b HELLP with newly diagnosed LAM and DAH	VV	14	Had lung biopsy for LAM during ECMO run	No	Preterm delivery at 24 weeks, NICU, respiratory/nutritional support	No
⁶⁹Creanga 2010	Case series	C/S	ARDS	26 year old at 32 weeks with H1N1 ARDS mechanically ventilated, C/S in ICU for maternal distress and hypotension, PNA and ARDS, septic shock, transferred for ECMO on PPD# 12	VV			Yes	Preterm delivery at 32 weeks, death	Yes
⁷⁰Cunningham 2006	Case report	VD	ARDS	33 year old at 24 weeks with ARDS requiring ECMO then post-cannulation 3 days developed HELLP	VV	3	Renal failure, 3 days after d/c ECMO vaginal bleeding and spontaneously delivered fetus at 25 weeks	No	Preterm delivery at 25 weeks, intubated to NICU and RDS	No
⁷¹Dabas 2018	Case report	C/S	Heart disease, cardiac arrest	32 year old with d-TGA s/p Mustard with RV dysfunction s/p C/S c/b cardiac arrest, CPR and ECMO support	VA then VV	3	N/A	No	N/A	No
⁷²DiLorenzo 2016	Case report	C/S	Cardiac failure, heart disease	Patient at 33 weeks with MV regurgitation due to prosthetic valve thrombosis with NYHA Class III HF planned C/S after VA ECMO and MV replacement, ECMO in OR immediately before c/s	VA	2	None	No	N/A	No
⁷³Ecker 2012	Case report	C/S	PPH, cardiac arrest	43 year old multiparous woman at 36 and 4/7 weeks with placenta previa with bleeding went to emergency C/S, upon closing fascia became unstable, PEA arrest underwent CPR and ECMO cannulation	VA	1	Bleeding, hysterectomy, need for HD, encephalopathy	No	N/A	N/A

⁷⁴Ellington 2011	Case series	N/A	ARDS	2 patients with postpartum H1N1 ARDS	N/A			1/2		N/A
⁷⁵Erb 2013	Case report	C/S	PPCM	32 year old G1P0 at 37 weeks with twin pregnancy c/b preeclampsia, PPD# 6 pulmonary edema EF 15% put on BiVAD, ECMO, IABP	N/A	1.5	None	No	N/A	N/A
⁷⁶Evans 2014	Case report	N/A	SCAD, cardiac failure	Patient with ACS on PPD# 14 diagnosed with SCAD to the LAD with EF 15-20% s/p CABG with failure to wean from CPB	VA	10	Rehab	No	None	N/A
⁷⁷Ezri 2009	Case report	N/A	PPCM	32 year old at 7 weeks with ectopic pregnancy s/p lap salpingectomy c/b SVT, pulmonary edema, hypoxemia, severe LV dysfunction EF 10-15% on VA ECMO and IABP	VA	7	Coagulopathy, hemolysis, thrombocytopenia, transfusions, hypertension led to discovery of pheo, resected during that admission, d/c home with mild left leg weakness	No	N/A	N/A
⁷⁸Fabricius 2001	Case series	C/S	Aortic dissection	32 year old G1P0 at 39 weeks with C/S for fetal tachycardia, found to have type A dissection with cardiogenic shock	CPB then VA	4	None	No	None	No
⁷⁹Faerber 2018	Case report	N/A	PPCM	23 year old with PPCM 1 month after delivery	VA	2	PPCM EF 10% and unstable s/p VA ECMO to LVAD on day 2 (HM3) explanted 1 year later	No	N/A	N/A
⁸⁰Fang 2016	Case report	C/S	Cardiac arrest, AFE	35 year old at 36 weeks with C/S c/b PEA requiring CPR (2.5 hours) and transfer to ECMO center, likely AFE	VA	2	Cardiogenic pulmonary edema, pulmonary hemorrhage, AKI, shock liver, DIC, mild right hand motor weakness	No	N/A	N/A

⁸¹Fayad 2007	Case report	C/S	Heart disease, cardiac failure	31 year old at 30 weeks with post-rheumatic mitral stenosis, dilated RV cannulated less than 1 week postpartum	VA	9	CPB then planned transition to ECMO for 9 days, VAP with pseudomonas then sepsis, died after ECLS decannulation	Yes	Preterm delivery at 30 weeks, NICU respiratory support	N/A
⁸²Fernandes 2015	Case report	C/S	PE, cardiac arrest	30 year old G1P0 at 37 and 5/7 weeks with cardiac arrest due to PE (got tPa) then CPR for 84 minutes until ECMO was running	VA then VV	4.75	Intraperitoneal bleeding, DIC, massive transfusion Harlequin syndrome, R arm compartment syndrome after R axillary cannulation requiring fasciotomies; VA 33 hours, VV 81 hours	No	N/A	N/A
⁸³Fernandez 2015	Case report	N/A	Malignancy, respiratory failure	24 year old at 22 weeks with infiltrates and effusion, giant cell NSCLC with respiratory failure	N/A		Refractory hypoxemia in setting of NSCLC	Yes	TAB at 22 weeks	Yes
⁸⁴Firstenberg 2010	Case report	C/S	Septic shock, cardiac failure	39 year old multiparous woman with necrotizing GAS soft tissue infection after c/s within 1 week of delivery with cardiomyopathy EF 5% LVAD to ECMO	VA	3	Multiple wound debridements, bleeding,	No	N/A	N/A
⁸⁵Fuchs 2017	Case report	C/S	ARDS	18 year old G1P0 at 36 and 2/7 weeks with human metapneumovirus c/b preeclampsia cannulated PPD# 1	VV	5	None	No	Preterm delivery at 36 weeks, respiratory support, NICU	No

⁸⁶Futoran 1975	Case series	C/S	AFE, PPH, cardiac failure	28 year old G2P2 at 34 weeks with placental abruption s/p C/S, DIC hysterectomy massive transfusion, AFE	VA	1.125	Necrotizing bronchopneumonia, renal thrombosis, hemopericardium, hemothorax, brain and adrenal hemorrhage	Yes	Stillborn	Yes
⁸⁶Futoran 1975	Case series	VD	Trauma, ARDS	19 year old G1P0 at 32 weeks with auto accident, multiple injuries ruptured spleen, liver tear, rib fractures, PTX, ARDS, PNA, septicemia cannulated after delivery	VA	14	Iliac vein thrombosis, renal failure, septicemia	Yes	Died day 2	Yes
⁸⁷Garcia-Aranda Dominguez 2017	Retrospective review	C/S	PAH	Patient with severe PAH cannulated postpartum	VV			Yes	N/A	N/A
⁸⁸Gattinoni 1980	Case series	C/S	ARDS	25 year old at 20 weeks with aplastic anemia, fetal demise s/p laparotomy, white out and ARDS	N/A	1.625	Pseudomonas peritonitis, septic shock 14 days after bypass	Yes	SAB at 20 weeks	Yes
⁸⁹Gauzere 2011	Retrospective review	C/S	ARDS	2 patients with H1N1 ARDS in third trimester	N/A		Both died	2/2	N/A	N/A
⁹⁰Gevaert 2011	Case series	C/S	PPCM	28 year old G3P1 with PPCM presented at 38 weeks, decompensated into cardiogenic shock with IABP placement c/b stillbirth via c/s, bedside ECMO cannulation and LVAD after 7 days	VA	7	VAP, bleeding at site of ECMO aortic cannula on day 1, d/c to home 37 days after admission and heart transplant 78 days post-LVAD	No	SAB at 38 weeks	Yes
⁹¹Gijs 2018	Case report	C/S	ARDS	30 year old at 26 weeks with ARDS Influenza A c/b hypoxemia, seizure, intracerebral hemorrhage	VV	12	Microbleeds in brain, seizure	No	Preterm delivery at 26 weeks, NICU	No

⁹² Goto 2017	Case series	C/S	Cardiac arrest	29 year old G1P0 at 36 weeks arrested in ambulance, CPR, perimortem cesarean delivery after 21 min, VA ECMO	VA	9	DIC, coagulopathy, emergent hysterectomy, massive transfusion	No	Preterm delivery at 36 weeks	No
⁹³ Grasselli 2012	Case report and literature review	VD	ARDS	25 year old G1P0 at 27 weeks with H1N1 ARDS, later delivered at term after recovery from H1N1 ARDS	VV	13	None reported	No	None	No
⁹⁴ Greenberg 1995	Case report	VD	ARDS	21 year old G1P0 delivered at 26 weeks with bacterial sepsis with staph aureus c/b arrhythmia, ARDS, multiorgan dysfunction cannulated within 1 month postpartum	ECCO ₂ (VV)	28	Bacterial sepsis c/b arrhythmia, ARDS, DIC, ischemic digits	No	Preterm delivery, RDS, IVH, spastic quadriplegia, developmental delay	No
⁹⁵ Grimme 2012	Case report	VD	Pulmonary hemorrhage, cardiac arrest	23 year old at 19 weeks with pulmonary hemorrhage c/b PEA s/p CPR 45 minutes until cannulation	VV	5	Hemothorax, tracheostomy, subsequent massive pulmonary hemorrhage	No	TAB bilateral ventriculomegaly, cerebral ischemia, counted toward fetal mortality	Yes
⁹⁶ Guenther 2015	Case report	C/S	AFE, cardiac arrest	43 year old G4P2 with AFE with cardiac arrest, PPH s/p hysterectomy, mobile ECLS called, CPR	VA	2.5	Intraperitoneal bleeding, re-laparotomy, renal failure, R hemiparesis, PEG, trach, d/c to rehab, neurologic deficits	No	N/A	No
⁹⁷ Guillaume 2013	Retrospective study	N/A	AFE	2 patients with AFE	VV			2/2		N/A
⁹⁸ Halldorsdottir 2016	Case report	C/S	Cardiac failure, heart disease	29 year old G3P1 delivered at 37 weeks with cardiogenic shock post C/S with severe hypoxemia, cannulated 2 hours after delivery due to MV prosthesis thrombosis subsequently repaired on PPD#3	VA	3	Weaned from CPB after MV replacement	No	None	No

⁹⁹ Hamdan 2017	Case series	N/A	PPCM	25 year old with PPCM EF 15-20%, VA ECMO to LVAD within 3 weeks postpartum	VA	4	None	No	N/A	N/A
¹⁰⁰ Hansen 2012	Case report	N/A	Heart disease, cardiac failure, sepsis	38 year old with septic shock for retained POC, D&C before IABP and then VA ECMO, then papillary muscle rupture, 2 days ECMO before MV replacement	VA	2	Severe AI went back to OR on POD9	No	N/A	N/A
¹⁰¹ Hara 2017	Case report	C/S	PAH	32 year old G2P1 delivered at 37 weeks with PAH with c/s c/b acute RV failure after delivery requiring cannulation	VA	2	None	No	Normal APGARs	No
¹⁰² Herrero 2018	Case series	C/S	PAH	30 year old G4P3 delivered at 32 and 4/7 weeks with group 1 PAH during pregnancy, worsening heart failure s/p c/s under general anesthesia c/b severe R sided failure cannulated 7 days postpartum	VA	9		Yes	Preterm delivery at 32 weeks, NICU admission	N/A
¹⁰³ Hill 1974	Case series	N/A	AFE, cardiac failure	26 year old with AFE	VA	1.125	Massive DIC, septicemia	Yes		N/A
¹⁰⁴ Ho 2009	Case report	C/S	AFE, cardiac arrest	33 year old G4P2 delivered at 38 weeks with placenta previa with bleeding went to emergency C/S for chest tightness, fetal bradycardia c/f AFE, PEA arrest underwent CPR and ECMO cannulation	VA	0.16667	Placenta previa/accreta and AFE c/b bleeding requiring hysterectomy, ECMO for 4 hours then ICU stay c/b ARDS and L sided weakness likely from ischemic event, d/c to rehab	No	None	No

¹⁰⁵ Ho 2014	Case report	C/S	PE, cardiac arrest	37 year old G2P1 delivered at 37 and 2/7 weeks with PEA arrest CPR for 10 minutes, VA ECMO found PE and underwent catheter directed thrombectomy	VA	6	Hemoperitoneum , need for UAE, no long term sequelae	No	N/A	N/A
¹⁰⁶ Holzgrae fe 2010	Observational study	N/A	ARDS	3 pregnant patients with H1N1 ARDS	N/A		N/A	No	1 baby died after 18 days of mom ECMO treatment	1/3
¹⁰⁷ Hou 2012	Case series	N/A		4 patients with H1N1 ARDS; 2 antepartum, 2 postpartum	VV			2/4		N/A
¹⁰⁸ Hsieh 2000	Case report	C/S	AFE, cardiac arrest	34 year old G7P3 with AFE on floor, emergency C/S, cardiac arrest with CPR, DIC, RV failure	VA	1.66667	DIC, massive transfusion, discharged home 24 days after delivery	No	N/A	N/A
¹⁰⁹ Huang 2017	Retrospective observational study	N/A		PPH (uterine atony for 4, AFE for 1), average time 32.6 +/- 18.8 hours	N/A		2 patients with official ECMO related bleeding complications		Median gestational age 37 weeks +/- 2.2 days	No
¹⁰⁹ Huang 2017	Retrospective observational study	C/S	AFE, cardiac arrest	39 year old G3P1 delivered at 34 weeks with twin pregnancy c/b previa with cesarean c/b cardiac arrest with 34 min CPR suspected AFE	VA	2	TAE, central hypothermia	No	Preterm delivery of twins at 34 weeks	No
¹⁰⁹ Huang 2017	Retrospective observational study	VD	PPH, cardiac arrest	41 year old G4P2 delivered at 39 weeks with PPH due to uterine atony, required CPR for 18 min, Postpartum 1h	VA	2.5	Subtotal hysterectomy, ex-lap internal bleeding	No	N/A	N/A
¹⁰⁹ Huang 2017	Retrospective observational study	VD	PPH	34 year old G1P1 delivered at 39 weeks with PPH due to uterine atony, DIC, Postpartum 1h	VA	0.41667	TAE	Yes	N/A	N/A
¹⁰⁹ Huang 2017	Retrospective observational study	VD	PPH, cardiac failure	33 year old G1P1 delivered at 38 weeks with PPH due to uterine atony, cardiomyopathy EF <35%. Postpartum 2h	VA	4.75	Subtotal hysterectomy, 18 hours VA ECMO then LVAD x 4 days	No	N/A	N/A

¹⁰⁹Huang 2017	Retrospective observational study	C/S	PPH, cardiac arrest	34 year old G2P1 delivered at 39 weeks with PPH after c/s due to uterine atony, DIC, TRALI, abruption, required CPR for 1 min, Postpartum 4h	VA, VV	2	TAE, Bakri, massive transfusion, VA 10 hours, VV 33 hours	No	N/A	N/A
¹¹⁰Huang 2017	Case report	N/A	Malignancy , respiratory failure	38 year old at 16 weeks with mediastinal mass, lymphoma c/b high airway pressures VV then PEA and VA ECMO	VV then VA		VV then PEA so VA, ECMO duration of days	No	N/A	N/A
¹¹¹Hur 2011	Case report	N/A	ARDS	29 year old at 32 and 4/7 weeks with H1N1 ARDS	N/A		Died	Yes	N/A	N/A
¹¹²Imaeda 2016	Case report	N/A	Septic shock, cardiac failure	24 year old multiparous woman delivered at 32 weeks with septic shock due to GAS with severe cardiomyopathy EF 10%	VA	7	Renal failure	No	N/A	No
¹¹³Isbir 2014	Case report	N/A	PPCM, cardiac arrest	29 year old delivered at 31 weeks with PPCM EF 25%, sternotomy for concert for aortic dissection, IABP, cardiac arrest, VA ECMO in OR	VA	2	None	No	Preterm delivery at 31 weeks, NICU	No
¹¹⁴Itagaki 2014	Case report	VD	PPH, cardiac arrest, cardiac failure	25 year old G2P2 delivered at 41 weeks with PPH, DIC prior to ECMO, Vfib arrest s/p shock recovered from DIC but PPD# 2 severe LV failure with hypoxic respiratory failure	VA	3	Required transfusions but no major bleeding, discharged from ICU day 10	No	N/A	N/A
¹¹⁵Ius 2015	Single center retrospective review	C/S	ARDS	31 year old G2P2 with respiratory failure requiring urgent c/s cannulated PPD# 1	VV	13	Intraabdominal bleeding following c/s requiring repeat laparotomies, dialysis, tracheostomy, died 3 weeks after ECMO wean	Yes	Unclear	N/A

116 Jacquens 2017	Retrospective observational study	N/A	ARDS	6 patients with ARDS in national database	N/A			No		N/A
117 Jais 2012	Case series	N/A	PAH	Patient case within series of patients with PAH; delivered then had RV failure requiring ECLS then heart/lung transplant	VA		N/A	No	N/A	N/A
118 Jandhyala 1994	Case report	VD	ARDS	20 year old G3P1 at 30 weeks with ARDS secondary to e.coli urosepsis with refractory hypoxemia for ECCO ₂ removal	ECCO ₂ (VV)	1.83333	None	No	Preterm delivery at 30 weeks, NICU	No
119 Janssen 2006	Case report	C/S	ARDS	36 year old G5P4 at 31 weeks with ARDS with multiorgan dysfunction from chlamydia psittaci, cannulated after delivery	PECLA (VV)		Renal failure, relaparotomy on POD2	No	Preterm delivery at 31 weeks, RDS, NICU	No
120 Jo 2011	Case report	C/S	PPCM	37 year old G4P0 at 37 weeks with PPCM with apical ballooning within 2 hours post C/S	VA	8	None	No	N/A	N/A
121 John 2012	Case report	C/S	Cardiac failure, heart disease	Presented with SOB, hypoxemia with refractory pulmonary edema from rheumatic valvular heart disease	VV	7	None	No	None	No
122 Ju 2018	Case series	C/S	Septic shock, ARDS	36 year old G2P1 at 21 weeks with twin pregnancy c/b chorioamnionitis, septic shock	VV	9	Fingertip amputation due to ischemia	No	TAB, twins	2/2
122 Ju 2018	Case series	VD	PPH, cardiac failure	37 year old G2P1 with uterine atony, PPH, cardiac dysfunction	VA	6	Hysterectomy, ligation of internal iliacs, DIC, massive transfusion, hematoma	No	N/A	No
122 Ju 2018	Case series	C/S	Cardiac arrest	30 year old G2P1 at 38 weeks with cardiotoxicity due to epidural, ECPR	VA then VV	13	Intraabdominal hematoma requiring washout	No	N/A	No
122 Ju 2018	Case series	C/S	AFE, cardiac failure	38 year old G2P2 with cardiogenic shock due to AFE	VA then VV	10	Hematoma, cognitive dysfunction	No	N/A	No

¹²³ Kapoor 2012	Case report	D&E	PAH, cardiac failure, cardiac arrest	39 year old G2P1 at 22 weeks with PAH and RV failure, planned D&E but post-procedure decompensated, PEA and went on VA support	VA		Underwent heart-lung transplant	No	TAB at 22 weeks (prior to ECLS)	Not counted as mortality
¹²⁴ Kaliyev 2015	Case report	N/A	ARDS	28 year old at 26 weeks with severe ARDS	VV	10	Blood transfusions	No	None	No
¹²⁵ King 2000	Case report	VD	Asthma, ARDS	29 year old at 25 weeks with asthma, PNA with ARDS with severe hypoxemia	VV	2.5	None	No	Preterm delivery at 31 weeks, NICU	No
¹²⁶ Kinni 2018	Case report	N/A	Diffuse alveolar hemorrhage	20 year old at 24 weeks with hemoptysis, diffuse alveolar hemorrhage, microscopic hemangiomas	VV		Worsening RV failure after VV, anatomical limitations to VA, pulmonary hemorrhage	Yes	N/A	N/A
¹²⁷ Knapp 2016	Case report	C/S	SCAD, cardiac failure	30 year old patient 16 days postpartum with SCAD s/p multiple stents s/p CABG SVGs to LAD and circumflex	VA	4	Post CABG BiV dysfunction EF 25% and moderate RV dysfunction	No	N/A	N/A
¹²⁸ Ko 1998	Case report	C/S	PPH, cardiac failure	37 year old G5P3 at 35 and 2/7 weeks with twins, placenta increta with bleeding and atony s/p UA ligation, methergine induced coronary vasospasm and pulmonary edema, LV EF 44% and arrhythmias on POD1 c/f postpartum MI	VA	4.16667	None	No	N/A	N/A
¹²⁹ Konstantinidis 2015	Case report	N/A	PAH, cardiac failure	35 year old at 37 weeks with idiopathic PAH with planned ECMO cannulation, unclear delivery but immediately after decompensated and was started on ECMO, BiV failure with RV pressure/volume overload	N/A	3	None	No	N/A	N/A

¹³⁰ Kuan-Ying 2017	Case series	N/A	PPH (3), AFE (1), PE (1)	5 patients; average age 36.8 +/- 3.9 years; average GA 36.98 +/- 2.6 weeks; PPH (3), AFE+PPH (1), PE (1); average 30+/-19.7 hours	VA	1.25	L hemiplegia in 1 patient	4/5	N/A	5/5
¹³¹ Kumar 2012	Case report	C/S	PPCM	32 year old G3 at 37 weeks with history of preeclampsia, mild peripartum pulmonary edema leading to C/S, progressive dyspnea, found to have EF10% and biventricular failure --> IABP without improvement --> BiVAD and ECMO on PPD#5	N/A	5	None	No	Twins	N/A
¹³² Krumnik I 2006	Case report	C/S	PPH, cardiac arrest, cardiac failure	39 year old woman with uterine atony and PPH treated with prostaglandins, cardiac arrest s/p CPR, EF <45%	VA	1.5	Myoclonic epilepsy, small visual field deficits	No	N/A	No
¹³³ Kunstyr 2010	Case report	VD	ARDS	28 year old at 24 weeks with H1N1 influenza A ARDS	VV	14	Hemorrhagic bronchitis, cephalic vein thrombosis, pseudomonas infection	No	Preterm delivery at 24 weeks, NICU, respiratory support	No
¹³⁴ Kutlesa 2011	Case series	VD	ARDS	23 year old at 24 weeks with H1N1 ARDS	VV	16	Fetal death, hyperbilirubinemia, severe tracheal hemorrhage	Yes	Fetal death, ischemia	Yes
¹³⁵ Law 2013	Case series	C/S	PPCM, Takotsubo, cardiac arrest, pheo	23 year old at 32 weeks with severe HTN, cardiac arrest c/b CPR, VT, shock, LVEF of 5% to ECMO	VA	1	Myocarditis EF5% increased by day 4 to 25-30% (Takotsubo)	No	Preterm delivery at 32 weeks, NICU admission	N/A
¹³⁶ Lee 1997	Case series	VD	ARDS	26 year old woman at 17 weeks with varicella PNA c/b ARDS	VA to VV	57	Cannula dislodgment, bilateral tension hemopneumothoraces, bronchopleural fistulas, multiple explorations for	Yes	SAB at 21 weeks	Yes

							bleeding, R heart failure, hepatic abscesses			
¹³⁶ Lee 1997	Case series	VD	ARDS	33 year old woman with varicella PNA c/b ARDS, cannulated PPD#3	VV	11	Staph PNA and renal insufficiency	No	N/A	N/A
¹³⁷ Lee 2008	Case report	C/S	PPH, TRALI	22 year old G3P2 at 40 weeks with PPH requiring multiple transfusions, TRALI with pulmonary edema	VA	3	None, discharged POD 33	No	N/A	N/A
¹³⁸ Legrand 2013	Case series	VD	AFE	26 year old G2P1 with operative vaginal delivery with forceps at term, AFE	VA	1	Hemorrhage, atony, AFE c/b PEA s/p hypogastric artery embolization, hysterectomy, RV dysfunction	Yes	N/A	N/A
¹³⁹ Lemaire 2017	Case series	N/A	Hemorrhage, cardiac arrest	30 year old at 32 weeks with splenic artery pseudoaneurysm rupture with hemoperitoneum, massive blood loss s/p coil embolization, return to OR for abdominal hemorrhage, cardiac arrest/pulmonary edema then ECMO, died hours later	N/A		Multiple organ failure, DIC	Yes	IUFD prior to ECLS - not counted in infant mortality	Not counted as mortality
¹⁴⁰ Lembrikov 2019	Case report	VD	Cardiac failure, Takotsubo, cardiac arrest	27 year old G2P0 at 40 and 6/7 weeks with vaginal delivery c/b manual removal placenta, PPH, atony, biventricular dysfunction requiring laparotomy/hysterectomy and intermittent CPR requiring ECMO support eventually regained function and d/c	VA	5	Post-operative IABP support; no neuro or cognitive deficit	No	N/A	N/A

¹⁴¹Li 2013	Case report	C/S	ARDS	28 year old G1P0 at 33 weeks with H1N1 ARDS c/b refractory hypoxemia, stat C/S then ECMO	VV	6	Staphylococcus hominis catheter infection	No	Preterm delivery at 33 weeks, NICU admission	No
¹⁴²Liu 2018	Case report	VD	ARDS	25 year old G2P1 at 24 weeks with H1N1 ARDS c/b fetal death on ECMO and vaginal delivery	VV	6	IUFD, vaginal bleeding, uterine contractions, IOL and VD, weaned from mechanical ventilation	No	IUFD at 24 weeks	Yes
¹⁴³Loizos 2017	Case report	N/A	Cardiac failure, pheo, Takotsubo	21 year old woman with pheochromocytoma, went for surgical termination of pregnancy, had HTN/bradycardia and pulmonary edema and then Takotsubo	VA	7	LV dysfunction EF 10-15%, discharged 7 days later	No	TAB - not counted for fetal mortality	Not counted as mortality
¹⁴⁴Lueck 2016	Case series	C/S	PPCM	34 year old G1P0 at 35 weeks with PPCM with hemodynamic shock, was on 10 days of ECLS prior to LVAD, eventually LVAD weaned after 612 days	VA	10	None	No	N/A	N/A
¹⁴⁵Lund 2011	Case report	VD	PPCM	37 year old G2P2 presented in acute CHF 8 days after delivery, intubated, EF 5-10% on ECMO for 4 days then LVAD	VA	4	N/A	No	N/A	N/A
¹⁴⁶Lysenko 2014	Case report	C/S	ARDS	24 year old G1P0 at 39 and 3/7 weeks with H1N1 ARDS, C/S at 30w3d	VV	17	None	No	Preterm delivery at 30 week, intubated, NICU admission	No
¹⁴⁷Marino 2018	Case report	C/S	PPH, AFE, cardiac arrest, PPCM	34 year old G2P1 at 38 weeks with cardiac arrest, uterine atony, DIC c/b PEA, AFE, LV EF 8%, VA ECMO with Impella	VA	7	PPH with DIC, bilateral UAE, abdominal hemorrhage, renal failure, multiple laparotomies for bleeding and massive transfusion	No	N/A	N/A

¹⁴⁸McDonald 2017	Case report	C/S	PE, cardiac arrest	22 year old at 36 weeks with PE c/b emergency C/S c/b instability with CPR for 65 min before ECMO cannulation	VA	5	Bleeding, bilateral UAE, ex-lap; arm compartment syndrome s/p fasciotomy, sepsis, re-ex-lap for bleeding, persistent R foot drop and R upper extremity flexion on discharge	No	Preterm delivery at 36 weeks, acidotic, did not survive	Yes
¹⁴⁹McKechnie 2001	Case report	C/S	SCAD, cardiac failure	Patient at 36 weeks with SCAD, p/w chest pain developed seizure and hemodynamic collapse, emergency C/S with CPR, shocks then ECMO with EF <10%, had angioplasty with 6 stents placed	VA	3	No complications	No	None	No
¹⁵⁰McNamee 2010	Case report	C/S	ARDS	21 year old G2P1 at 33 weeks with H1N1 complicated by PTX, hypoxia requiring ECMO on PPD#5, pulmonary hemorrhage requiring R middle lobectomy c/b bronchopleural fistula	VA	28	Pulmonary hemorrhage, generalized myopathy, neuro-rehabilitation	No	None	No
¹⁵¹Mendes 2012	Case report	N/A	ARDS	42 year old woman with H1N1 ARDS 2 weeks postpartum	VV	7	None	No	N/A	N/A
²³Meng 2017	Retrospective review, 4 centers	C/S	PAH	Patient at 31 weeks with PAH due to CHD or VSD/Eisenmenger cannulated PPD#4	VA		N/A	Yes	Preterm delivery at 31 weeks, NICU admission	No
²³Meng 2017	Retrospective review, 4 centers	C/S	PAH	Patient at 34 weeks with PAH due to CHD or VSD/Eisenmenger cannulated PPD#3	VV then VA	13	VV 2d then VA 11d	Yes	Preterm delivery at 34 weeks	No

²³Meng 2017	Retrospective review, 4 centers	C/S	PAH	Patient at 35 weeks with PAH due to CHD or VSD/Eisenmenger, cannulated 2 days before delivery	VV then VA	21	Discharged home on PPD24 found dead at home on PPD89 - ultimately died but not while on ECMO, VV 15d then VA 6d	No	Preterm delivery at 35 weeks	No
²³Meng 2017	Retrospective review, 4 centers	D&E	PAH	Patient at 13 weeks with idiopathic PAH	N/A		N/A	Yes		Yes
²³Meng 2017	Retrospective review, 4 centers	D&E	PAH	Patient at 21 weeks with scleroderma, pulmonary HTN cannulated PPD#8	VA		N/A	Yes		Yes
²³Meng 2017	Retrospective review, 4 centers	C/S	PAH, cardiac arrest, malignancy	Patient at 34 weeks with thrombotic disease from cancer, PEA arrest cannulated PPD#1	VA		N/A	Yes	Preterm delivery at 34 weeks	No
¹⁵²Meng 2018	Case report	D&E	Heart disease, cardiac failure	21 year old G1P0 at 22 weeks with Eisenmenger syndrome, VSD underwent planned D&E at 21 weeks for maternal risk c/b post-procedure respiratory decompensation	VV	3	Upper extremity DVT POD 8, discharged on POD35	No	D&E	Yes
¹⁵³Miessau 2015	Case report	VD	PPCM	22 year old with severe cardiomyopathy EF <10% bridge to decision cannulated PPD 14	VA then VV	22	Dialysis, MARS for shock liver, severe respiratory failure after TAH, tracheostomy; underwent OHT 103 days after TAH implantation; VA unclear, VV 12 days then rescue 10 days (22 days of VV support after TAH)	No	N/A	No

¹⁵⁴ Mikami 2018	Case report	C/S	PPCM	38 year old G3P2 at 35 and 6/7 weeks with PPCM EF10% given IABP and ECMO prior to C/S	VA	8	Uterine bleeding s/p Bakri, TAE, hysterectomy	No	Preterm delivery at 35 weeks, neonatal asphyxia, therapeutic hypothermia, NICU	No
¹⁵⁵ Mita 2017	Case report	C/S	Cardiac arrest, pheo	29 year old G4P1 at 37 weeks with C/S complicated by hemodynamic collapse, concern for AFE admitted to ICU, PEA with CPR then IABP+ECMO found to have pheochromocytoma	VA	6	DIC, renal failure, rhabdomyolysis; pheo resected on POD70, left ICU and discharged 142 days postpartum no neurologic deficits	No	N/A	N/A
⁷ Moore 2016	Case report, Systematic review	N/A	ARDS, cardiac failure	25 year old G2P1 at 18 weeks with hantavirus cardiopulmonary syndrome	VA	3	Bleeding requiring transfusion	No	Preterm delivery at 35 weeks	No
¹⁵⁶ Morsolini 2017	Case series	C/S	PAH	Patient with PAH	VA	1.08333	SVC and PA thrombosis	No	Preterm delivery	No
¹⁵⁶ Morsolini 2017	Case series	C/S	ARDS	Patient with H1N1	VV	31	Gastrointestinal bleeding, fetal IVH	No	Preterm delivery, IVH, discharged	No
¹⁵⁶ Morsolini 2017	Case series	C/S	Heart disease, heart failure	Patient with mitral prosthesis thrombosis	VA	1.5	PNA	No	Preterm delivery	No
¹⁵⁶ Morsolini 2017	Case series	C/S	PAH	Patient with PAH	VA	0.91667	Uterine bleeding, discharged POD22	No	Preterm delivery	No
¹⁵⁷ Nair 2011	Retrospective observational study	VD (5) VAVD (2) C/S (5)		5 spontaneous, 2 VAVD and 5 C/S (3 after ECMO, 1 after ECMO started, 1 prior to ECMO), all postpartum patients were within 1 week of delivery	N/A				Preterm birth average 31 weeks	
¹⁵⁷ Nair 2011	Retrospective observational study		ARDS	34 year old at 26 weeks with H1N1 ARDS cannulated antepartum	VV	18		No	N/A	No
¹⁵⁷ Nair 2011	Retrospective observational study		ARDS	22 year old at 13 weeks with H1N1 ARDS cannulated antepartum	VV	2		No	N/A	No

157 Nair 2011	Retrospective observational study		ARDS	23 year old at 21 weeks with H1N1 ARDS cannulated antepartum	VV	11		No	N/A	No
157 Nair 2011	Retrospective observational study		ARDS	33 year old at 23 weeks with H1N1 ARDS cannulated antepartum	VV	5	Uterine bleeding	No	Stillborn	Yes
157 Nair 2011	Retrospective observational study		ARDS	42 year old at 20 weeks with H1N1 ARDS cannulated antepartum	VV	20	Pulmonary bleeding	No	Stillborn	Yes
157 Nair 2011	Retrospective observational study		ARDS	39 year old at 26 weeks with H1N1 ARDS <1 day cannulated antepartum	VV		Multiple bleeding sites	Yes	N/A	No
157 Nair 2011	Retrospective observational study		ARDS	29 year old at 30 weeks with H1N1 ARDS cannulated antepartum	VV	20	Intracranial bleeding	Yes	N/A	No
157 Nair 2011	Retrospective observational study		ARDS	27 year old patient with H1N1 ARDS	VA to VV	17	Limb ischemia, ECMO cannula bleeding	Yes	N/A	No
157 Nair 2011	Retrospective observational study		ARDS	29 year old patient with H1N1 ARDS	VV	10		No	N/A	No
157 Nair 2011	Retrospective observational study		ARDS	23 year old patient with H1N1 ARDS	VV	27	Pulmonary bleeding	Yes	N/A	No
157 Nair 2011	Retrospective observational study		ARDS	27 year old patient with H1N1 ARDS	VV	15	ECMO cannula bleeding	No	N/A	No
157 Nair 2011	Retrospective observational study		ARDS	32 year old patient with H1N1 ARDS	VA to VV	12	Limb ischemia, fasciotomy	No	N/A	No
158 Nair 2017	Case report	VD	PAH, cardiac failure	29 year old patient with PAH, hemoptysis, RV failure cannulated PPD#11	VA then VV		VA then VV ECMO after lung transplant, d/c 1 month post-transplant	No	N/A	N/A

159Naqvi 2018	Case report	VD	PPCM	32 year old patient with ALL s/p chemo with LV EF 15% and RV thrombus, IOL and delivery c/b acute DVT and PE, edema to ECMO bridge to transplant	VA	60	Multiple circuit changes, heart transplantation on day 60	No	N/A	No
160Neurath 1993	Case report	C/S	ARDS	32 year old patient at 26 weeks with ARDS due to malaria cannulated PPD# 17	ECCO ₂ (VV)	12	Tracheotomy, 11 week hospital stay	No	Preterm delivery at 26 weeks, NICU admission	No
161Ngatchou 2012	Case report	N/A	ARDS	28 year old G2P1 at 32 weeks with urosepsis with e.coli c/b ARDS	VV	2	None reported	No	N/A	N/A
162Noah 2010	Case series	C/S	ARDS	23 year old at 32 weeks with ARDS due to s. aureus p/w hemoptysis intubated emergency c/s worsening status despite NO	VV	23	Hemothorax, PTX, CVVH, MARS	No	N/A	N/A
163O'Gara 2009	Case report	C/S	Malignancy , heart failure	28 year old at 32 and 4/7 weeks with mediastinal mass s/p pericardial window, depressed LV EF on ECMO day 7, later underwent sternotomy and diagnosed with lymphoma	VA	9	Sternotomy for biopsy, underwent chemo while on ECMO, later hospital course c/b seizures, candida fungemia, d/c to rehab then home; of note, she died 10 months later	No	Preterm delivery at 32 weeks, NICU	No
164Pagel 2009	Case report	C/S	Cardiac arrest	24 year old at 24 weeks with Brugada syndrome c/b difficult to control VT episodes, multiple ICD shocks starting at 20 weeks, had arrest requiring shocks and emergency C/S	VA	3	Groin re-exploration and pseudoaneurysm	No	Preterm delivery at 24 weeks, NICU	No
165Panarell o 2010	Case series	C/S	ARDS	H1N1 ARDS, ECMO mean 16 days; 1 patient delivered on ECMO	N/A		Mean LOS 37 days			No
165Panarell o 2010	Case series	N/A	ARDS	38 year old at 25 weeks with H1N1 ARDS	N/A	16	Study mean LOS was 37 days	No	Preterm delivery at 25 weeks, NICU	No

165Panarell o 2010	Case series	N/A	ARDS	31 year old at 33 weeks with H1N1 ARDS	N/A	16	Study mean LOS was 37 days	No	Preterm delivery at 33 weeks, NICU	No
165Panarell o 2010	Case series	N/A	ARDS	23 year old at 39 weeks with H1N1 ARDS	N/A	16	Study mean LOS was 37 days	No	Preterm delivery at 33 weeks, NICU	No
166Panarell o 2011	Case report	C/S	ARDS	38 year old at 25 weeks with H1N1 ARDS cannulated antepartum	VV	35	C/S at 30 weeks to improve pulmonary mechanics, GI bleed requiring endoscopic intervention	No	Preterm delivery at 30 weeks, intracranial hemorrhage, intubation, NICU	No
167Park 2014	Case report	C/S	PPCM	34 year old G2P1 at 37 weeks with PPCM EF 39% worsening HF planned VA ECMO prior to C/S due to concern to abrupt decreased cardiac output	VA	6	None	No	NICU admission, respiratory support	No
168Parkins 2007	Case report	C/S	ARDS	16 year old G1P0 at 32 weeks with influenza ARDS	VV	13	Emergency C/S due to ineffective ECMO flow rate from uterine compression, infections, renal failure, mild anoxic brain injury, pancreatitis, polyneuropathy	No	Preterm delivery at 32 weeks, NICU admission	No
169Paruchu ri 2018	Retrospective cohort	N/A	ARDS	Limited details but reported 2 patients with no mortalities	N/A			No		N/A
170Patel 2017	Case report	C/S	Distributive shock	34 year old G1P0 with preeclampsia c/b distributive shock postpartum, laparotomy, liver dysfunction listed for liver transplant supported with VV ECMO	VV	9	Liver transplant done while on ECMO, discharged home day 43	No	N/A	N/A
171Patroniti 2011	Case series	N/A	ARDS	Patient at 22 weeks with H1N1 ARDS	N/A		N/A	No		N/A

¹⁷¹Patroniti 2011	Case series	N/A	ARDS	3 postpartum patients (<28 days) who presented with H1N1 ARDS	N/A		N/A	No		N/A
¹⁷²Patrut 2015	Case report	C/S	ARDS	32 year old woman at 26 weeks with H1N1 severe ARDS, C/S 1 day after decannulation	VA	8	Femoral artery vascular complications requiring thrombectomy, angioplasty, infected groin wound, ECMO arterial cannula dislodged	No	Preterm delivery at 27 weeks, NICU admission	Yes
¹⁷³Pechulis 2014	Case report	N/A	ARDS	24 year old woman with H1N1 ARDS c/b prolonged ECMO	VV	72	Femoral artery repair, pelvic hematoma and ex-lap, cholecystectomy, bacteremia, pulmonary HTN, profound weakness, d/c to rehab	No	N/A	N/A
¹⁷⁴Pekka 2013	Case report	C/S	PE, cardiac failure	Patient with massive PE 21 days postpartum, RV failure used as bridge to decision (medical management in this case)	VA	2	None	No	N/A	N/A
¹⁷⁵Perdue 2018	Case report	N/A	ARDS, cardiac failure, septic shock	24 year old patient 2 days postpartum with septic shock from GAS c/b hypotension, ARDS, cardiomyopathy EF <10%	VA	4	Hysterectomy for endometritis, dry gangrene, asthenia, rehab, depression, using walker, chronic foot pain	No	N/A	No
¹⁷⁶Pereira 2018	Case report	C/S	Pulmonary alveolar proteinosis	21 year old patient at 32 weeks with pulmonary alveolar proteinosis c/b hypoxia, VV ECMO done postpartum for BAL	VV		None	No	Preterm delivery at 32 weeks, NICU admission	N/A

¹⁷⁷ Pham 2013	Cohort	N/A	ARDS	18 patients with H1N1 ARDS	N/A		IUFD at 21 weeks in one case, preterm delivery at 34 weeks and NICU admission but survived	4/18	IUFD at 21 weeks, Preterm delivery at 34 weeks and NICU admission	N/A
¹⁷⁸ Phillips 2017	Case report	C/S	Aspiration pneumonitis, ARDS	25 year old G2P1 at 21 weeks with hyperemesis gravidarum with aspiration pneumonitis c/b acute hypoxic respiratory failure with ARDS	VV	6	C/S 5 weeks after ECMO	No	Preterm delivery at 26 weeks, NICU, RDS	No
¹⁷⁹ Piatrovich 2018	Case report	C/S	PPH, cardiac arrest	22 year old with PPH s/p VF with CPR, pulmonary edema with IABP and ECMO	VA	10	Lamellar dural hematoma, abdominal bleeding requiring ex-lap, transfer to floor on day 13	No	N/A	N/A
¹⁸⁰ Pirsaheli 2012	Case report	N/A	Propofol infusion syndrome, cardiac arrest	20 year old woman with status epilepticus treated with propofol, developed PRIS with VT/Vfib went onto ECMO	N/A	5	Cerebral artery infarct attributed to cardiac embolism	No	N/A	N/A
¹⁸¹ Plotkin 1994	Case report	C/S	Trauma, ARDS	25 year old patient at 28 weeks with GSW to R chest, fetal bradycardia s/p c/s, lung lacerations, massive transfusion c/b ARDS	VA	1.70833	Renal failure, no ECMO complications	No	Preterm delivery at 28 weeks, NICU	Yes
¹⁸² Power 2011	Case series	N/A	ARDS	37 year old patient at 23 weeks with H1N1 ARDS	VV	6	Critical illness polyneuropathy, d/c to rehab, transfusions required	No	Stillborn	Yes
¹⁸³ Prakash 2014	Case report	C/S	Tracheal tumor	23 year old patient at 32 weeks with respiratory distress due to pedunculated tracheal tumor, underwent tumor debulking on PPD#1 with precautionary VV ECMO cannulation - lobular capillary hemangioma	VV		Bleeding during tracheal tumor resection, VV ECMO rescue	No	Preterm delivery at 32 weeks, NICU admission	No

¹⁸⁴Rabin 2012	Case report	C/S	ARDS	22 year old patient with postpartum wound infection c/b ARDS with prolonged respiratory failure, traction bronchiectasis, lung transplant on CPB after 155 days	VV	155	None	No	N/A	N/A
¹⁸⁵Rademacher 2010	Case report	C/S	PPCM, heart disease, heart failure	36 year old woman at 39 weeks with PPCM, severe ischemic heart disease, s/p multiple stents cannulated PPD#2	N/A	4	PNA, extubated and decannulated, however day 17 condition worsened and found to have total LV necrosis	Yes	N/A	N/A
¹⁸⁶Radsel 2018	Case report	VD	ARDS	29 year old G1P0 at 23 weeks with H1N1 ARDS	VV	10	Decannulated on day 5 then recannulated, preterm labor, critical illness polyneuropathy, trach, rehab	No	Preterm delivery at 25 weeks, NICU, intubated, BPD, NAS from maternal sedation	No
¹⁸⁷Raley 2015	Case report	C/S	Asthma	18 year old patient at 37 weeks with status asthmaticus, hypercarbic respiratory failure s/p C/S with elevated airway pressures for AVCO ₂ removal	AVCO ₂ (VV)	3	None	No	N/A	N/A
¹⁸⁸Ramirez 2018	Case report	N/A	PPCM	29 year old G2P1 at 23 weeks with cardiomyopathy EF 25%, giant cell myocarditis c/b IUFD, IABP and ECMO	VA		Uterine bleeding requiring transfusions, ectopy	No	IUFD at 23 weeks	Yes
¹⁸⁹Rein 2014	Case report	VD	ARDS	38 year old woman delivered at 37 weeks with postpartum ARDS due to influenza B, MRSA	N/A		ARDS, multiple organ failure, transferred for ECMO but no details of cannulation or duration	Yes	NICU	No

¹⁹⁰ Reyftmann 2006	Case report	C/S	PPH, cardiac arrest, cardiac failure	36 year old G2P1 at 37 weeks with C/S for twins developed PPH cardiac arrest with EF<10% CPR x2 hours then ECMO	VA	6.25	Attempted B lynch, bilateral UAligation, subtotal hysterectomy; secondary coagulopathy and need for ex-lap on POD1 for hemoperitoneum	No	One twin went to NICU for acidosis	No
¹⁹¹ Riddell 2004	Case report	C/S	ARDS	33 year old at 37 weeks with C/S for twins and HELLP c/b hypoxemia, hypotension, ARDS transfer for ECMO on PPD3	VA	21	Ascites, ischemic colon s/p ex-lap, coagulopathy, renal failure on dialysis, intracerebral hemorrhage	Yes	N/A	No
¹⁹² Riester 2015	Case series	C/S	Cardiac failure, pheo, Takotsubo	25 year old patient presented with hypertensive crisis, emergency c/s c/b Takotsubo cardiomyopathy secondary to pheo, pulmonary edema	VA		None	No	None	No
¹⁹³ Robbins 2015	Case report	C/S	Asthma	30 year old at 16 weeks with asthma, pneumococcal PNA respiratory failure	VV	9	None	No	Preterm delivery at 36 weeks	N/A
¹⁹⁴ Roberts on 2010	Case report	C/S	ARDS	27 year old G3P1 at 24 weeks with H1N1 ARDS	VV	17	Vaginal hemorrhage, trach	No	None	No
¹⁹⁵ Rodriquez Chaverri 2018	Case report	N/A	PPCM	33 year old woman with postpartum biventricular dysfunction	VA	7	Heart transplant after 7 days	No	N/A	N/A
¹⁹⁶ Roncon-Albuquerque 2012	Case series	C/S	ARDS	36 year old woman with H1N1 ARDS cannulated on PPD#13	VV	39		Yes	N/A	N/A

¹⁹⁷ Rubin 2013	Case report	C/S	PE, cardiac failure	38 year old G2P0 at 25 and 3/7 weeks with hypoxia, hypotension, seizure-like activity underwent emergent C/S found to have RV straight, PE with failed suction thrombectomy c/b DIC and shock then put on VVA ECMO	VVA	8	DIC prior to ECMO, abdominal compartment syndrome requiring bedside laparotomy and hematoma evacuation	No	Preterm delivery at 25 weeks, NICU	N/A
¹⁹⁸ Sakamoto 2018	Case report	C/S	Heart disease, cardiac arrest	36 year old G2P1 at 38 weeks with history of WPW s/p cardiac arrest, VF s/p ACLS, perimortem C/S to ECMO	N/A	3	Cardiac dysfunction, postpartum bleeding, coagulopathy	No	Hypoxic encephalopathy, NICU	No
¹⁹⁹ Sakanashi 1994	Case report	C/S	Heart disease, cardiac failure	32 year old with postpartum dyspnea 33 days after delivery, R heart failure, hypoxemia, Eisenmenger's	VA	3.66667	None during ECLS, died 57 days after decannulation of sudden cardiac arrest	No	N/A	N/A
²⁰⁰ Salazar 2017	Retrospective review	N/A	Dengue	31 year old at 30 weeks with preeclampsia, induced labor at 30 w, postpartum c/b refractory thrombocytopenia and hypoxemic respiratory failure requiring MV and ECMO found to have dengue	VV	1.5	Bradycardia during cannulation	Yes	N/A	N/A
²⁰¹ Satoh 2002	Case report	C/S	PAH, cardiac failure	33 year old G1P0 at 18 weeks with PAH with mean 70s and worsening of symptoms, termination of pregnancy on ECMO	VA	19	Coagulation of artificial lung requiring changing	Yes	TAB, included in infant mortality	Yes
²⁰² Scherrer 2012	Case report	C/S	Heart disease, cardiac failure	24 year old at 36 weeks with tachycardia induced CM secondary to chronic SVT, ECMO on PPD1 then RFA on ECMO successfully terminated rhythm	VA	4	Confusion, amnesic disorder, Sheehan's	No	None	No
²⁰³ Scriven 2009	Case series	C/S	ARDS	31 year old at 33 weeks with H1N1 ARDS	N/A		N/A	No	Preterm delivery at 33 weeks	No

²⁰⁴ Seczynska 2014	Case report	C/S	ARDS	33 year old at 28 weeks with H1N1 ARDS cannulated PPD#9	VV	21	Bilateral pneumothoraces, R hemothorax	No	Preterm delivery at 28 weeks prior to ECMO, NICU admission	N/A
²⁰⁵ Seidler 2016	Case report	C/S	ARDS, malignancy	29 year old at 29 weeks with respiratory distress, metastatic choriocarcinoma after c/s on PPD#2	VV	5	None	No	Preterm delivery at 29 weeks, NICU	N/A
²⁰⁶ Sellami 2017	Case report	N/A	PPCM	29 year old with ectopic pregnancy s/p laparotomy c/b LV failure EF 20% myocarditis	VA	15	Discharged to rehab	No	Ectopic pregnancy	N/A
²⁰⁷ Seong 2018	Case report	VD	Cardiac arrest	32 year old at 39 weeks with SROM c/b seizure and hypotension then CPR, VT, LV dysfunction, DIC plan for ECMO 1 hour after arrest	VA	1	Massive transfusion, DIC (AFE)	No	None	No
²⁰⁸ Seth 2018	Case report	N/A	Asthma	32 year old G2P1 at 23 weeks with status asthmaticus, hypoxic respiratory failure	VV		N/A	No	N/A	No
²⁰⁹ Shah 2014	Case report	C/S	ARDS, cystic fibrosis	22 year old at 29 and 5/7 weeks with influenza A, cystic fibrosis, hypercapnic respiratory failure requiring ICU cannulated 3 weeks after delivery	VV	39	Multiorgan failure, worsening CF plan to bridge to lung transplant however required inotrope and multiorgan failure; awake ECMO 3 weeks into ICU stay started as bridge to salvage lung transplant for CF, died after 60 days in ICU	Yes	Preterm delivery at 32 weeks, NICU admission	No
²¹⁰ Shamsah 2017	Case report	VD	PAH, cardiac arrest	25 year old G2P1 at 26 weeks with pulmonary hypertension, heart failure s/p arrest during labor, delivered amidst CPR and ECMO cannulation	VA	14	Prepared for heart/lung transplant but abruptly decompensated and died after ECLS	Yes	Preterm delivery at 26 weeks, NICU	N/A

⁸ Sharma 2015	Case series, Systematic review	N/A	ARDS	Patient at 25 weeks with mycoplasma ARDS	VV	5	Minor bleeding at trach and ECMO catheter site	No	N/A	No
⁸ Sharma 2015	Case series, Systematic review	N/A	ARDS	Patient on PPD#1 with influenza A ARDS	VV	4	Minor vaginal bleeding	No	N/A	No
⁸ Sharma 2015	Case series, Systematic review	VD	Cardiac failure	Patient at 34 weeks with cardiogenic shock likely viral	VA	6	STEMI, vaginal bleeding, clot in circuit	No	Preterm delivery at 34 weeks, stillborn	Yes
⁸ Sharma 2015	Case series, Systematic review	N/A	PPCM, ARDS	Patient on PPD#2 with peripartum cardiomyopathy ARDS unknown	VV	6	Minor vaginal and trach site bleeding	No	N/A	No
²¹¹ Shen 2009	Case report	C/S	AFE, cardiac arrest	21 year old G2P1 at 33 weeks with AFE c/b PEA to ECMO	VA	1	None	No	Preterm delivery at 33 weeks	No
²¹² Shuang 2016	Case report	C/S	ARDS	40 year old at 35 weeks with ARDS from H5N6 cannulated PPD# 2	N/A	46	Multiorgan failure, pulmonary HTN, died on day 50	Yes	N/A	N/A
²¹³ Sim 2012	Case report	C/S	Cardiac failure, cardiac arrest	28 year old at 26 weeks with refractory SVT with cardiogenic shock crashed to ECMO, had IUFD, had RFA, later c/s	VA	7	None reported	No	SAB at 26 weeks	Yes
²¹⁴ Skolnik 2017	Multicenter, retrospective cohort	N/A	AFE	4 patients with AFE	VA		2 ECMO died within first few hours, 1 CPB died, 1 major 1 minor neurologic morbidity, not including CPB	2/4		N/A
²¹⁵ Smiechowicz 2011	Case report	C/S	ARDS, cardiac arrest	37 year old with postpartum H1N1 ARDS (5 weeks PP) c/b PEA and hypercarbia requiring CO2 removal, required dialysis, discharged on day 24	VV	8.5	Started CO2 removal x 6 days, then off for 36 h then resumed on day 8 for another 60 h	No	N/A	N/A

²¹⁶Smith 2009	Case report	VD	PPH, PPCM	19 year old G2P0 at 38 weeks with PPH requiring uterotonics, emergency hysterectomy, massive transfusions, TTE with LV EF 25%, bradycardic arrests requiring CPR, TEE EF <5%, external cardiac massage then VA ECMO	VA	2.83333	None	No	N/A	N/A
²¹⁷Stankiewicz 2011	Case report	C/S	ARDS	23 year old at 37 weeks with H1N1 ARDS cannulated 12 days postpartum	VV	26	PTX, thoracotomy, replacement of oxygenator	No	N/A	N/A
²¹⁸Steinack 2017	Case report	N/A	Asthma	25 year old at 5 weeks with status asthmaticus with hypoxic respiratory failure despite maximal medical therapy	VV	2	Retrochorial hematoma, resolved and went on to delivery healthy boy at 38 weeks; discharged 9 days later	No	None	No
²¹⁹Strecker 2012	Case report	VD	Cerebral venous thrombosis, ARDS	28 year old with cerebral venous thrombosis c/b R frontal lobe edema s/p craniectomy c/b ARDS cannulated 15 days postpartum	VV	110	Multiple infections	No	N/A	N/A
²²⁰Su 2014	Retrospective review	C/S	PPCM	32 year old at 30 weeks with PPCM in 3rd trimester, emergency c/s for maternal distress represented 1 month later after collapse	VA	5	None	Yes	Preterm delivery at 30 weeks, NICU admission	N/A
²²⁰Su 2014	Retrospective review	C/S	PPCM	27 year old at 34 weeks with PPCM in 3rd trimester, emergency c/s for maternal distress represented 1 month later after collapse	VA	8.5	None	No	Preterm delivery at 34 weeks	N/A
²²¹Takacs 2018	Case report	VD	Cardiac arrest, ARDS	21 year old G3P2 at 24 weeks with cardiac arrest with CPR, SROM during resuscitation, pulmonary contusions and ARDS	VA	7	SAB during collapse, DIC while on ECLS, possible due to IUFD so underwent IOL,	No	IUFD prior to ECLS	Not counted in mortality

							VAVD, retained POC, subsequent D&C on ECMO			
²²² Takeda 2012	Case series	N/A	ARDS	Patient with H1N1 ARDS	VV			No		N/A
²²³ Tampo 2014	Case report	N/A	PPCM	32 year old G1P0 at 39 and 5/7 weeks with PPCM, LV EF 33% cannulated PPD#3	VA	5	None	No	N/A	N/A
²²⁴ Theodorou 2015	Case report	N/A	Asthma	38 year old G1P0 at 16 weeks with status asthmaticus, hypercarbic respiratory failure	VV	8	Severe mucosal bleeding, small intracerebral hemorrhage	No	Ventriculomegaly	N/A
²²⁵ Tinckres 2018	Case report	C/S	AFE, ARDS, cardiac arrest	35 year old G1P0 at 39 weeks with hypoxia, DIC, AFE c/b cardiac arrest, PPH, hysterectomy, ARDS, RV failure onto ECMO	VA	4	Hemorrhagic shock before ECMO from AFE	No	N/A	N/A
²²⁶ Ull 2017	Case report	C/S	PPCM	26 year old multiparous woman at 34 weeks with placenta previa increta, C/S with hysterectomy cannulated immediately postpartum	VV	71	PPCM with EF <20%, need for intermittent dialysis; made full recovery by 12 months	No	Preterm delivery at 34 weeks, NICU	No
²²⁷ Unterberg 2017	Case report	VD	ARDS	29 year old G1P0 at 38 weeks with HELLP c/b several intracerebral hemorrhage and coagulopathy s/p EVD c/b pseudomonas PNA and ARDS with refractory hypercapnia cannulated PPD# 9	VV (iLA)	42	Severe neurological dysfunction, IVH, tracheostomy, rehab, 42 days ECMO then 10 additional days of iLA	No	NICU admission	No
²²⁸ Uribarri 2017	Case series	N/A	ARDS	Patient with ARDS due to influenza A during pregnancy	VV	2	Bleeding	Yes	N/A	N/A

²²⁹ Van Zwet 2016	Case report	C/S	Cardiac failure, cardiac arrest, pheo, Takotsubo	27 year old at 35 and 2/7 weeks who presented with respiratory distress, hypertensive crisis, fetal bradycardia -> emergency C/S with refractory hypotension, pulmonary edema and PEA x2, TEE with EF 20-25% to VA ECMO, found to have pheo removed 22 days after initial event	VA then VV	7	VA 5 days, VV 2 days	No	Preterm delivery at 35 weeks, intubated, NICU	No
²³⁰ Veld-van Wingerden 2015	Case report	VD	ARDS	22 year old G5P3 at 18 weeks with ARDS due to strep pyogenes PNA/ARDS, pregnancy loss prolonged ECMO course cannulated after spontaneous abortion	VV	108	Enterococcus septicemia, massive hemothorax, pulmonary hemorrhage, circuit changed 5 times, trach, rehab	No	SAB at 18 weeks	Yes
²³¹ Verroust 2007	Case report	VD	AFE, cardiac arrest	29 year old G3P2 at 35 weeks with termination for porencephaly so ruptured membranes, 15 minutes later had cardiac arrest TTE with RV failure, delivered fetus within 1 hour then massive bleeding, transferred hospital, EF <15% went onto ECLS	VA	20	Bleeding prior to ECLS related to AFE	No	N/A	Yes
²³² Visveswaran 2016	Case report	C/S	Septic shock, PPCM	31 year old at 23 weeks with sepsis c/b cardiomyopathy, LV dysfunction EF 25-30% treated with IV T3	VV	6	None, discharged home on day 20	No	None	No
²³³ Vitulo 2017	Case series	C/S	PAH, cardiac arrest	31 year old at 32 weeks with pre-capillary PAH Group V, scheduled c/s c/b post-delivery cardiac arrest, RV dysfunction so went onto ECMO	VA	1	None	No	Preterm delivery at 32 weeks, NICU admission	N/A

²³³ Vitulo 2017	Case series	C/S	PAH	31 year old at 32 weeks with pre-capillary PAH Group I, scheduled c/s with planned pre-incision ECMO	VA	1	Urgent re-laparotomy for bleeding on POD3, thought not to be related to ECMO	No	Preterm delivery at 32 weeks, NICU admission	N/A
²³⁴ Wall 2010	Case report	N/A	Cardiac arrest	39 year old G2P1 at 18 weeks with acute PEA, out of hospital arrest	VA	3	Compartment syndrome of lower extremity requiring fasciotomy, planned AKA but due to neurological damage withdrew care	Yes	Maternal PE at 18 weeks	Yes
²³⁵ Wang 2015	Case report	VD	ARDS	29 year old at 27 weeks with H7N9 ARDS	VV then VA	19	AF, heart failure, sepsis due to acinetobacter, PE; VV 4 days VA 15 days	Yes	SAB delivered 4 days after loss of fetal heart tones	Yes
²³⁶ Wei 2011	Case report	C/S	PE, cardiac arrest	36 year old G1P1 delivered at 37 weeks with PE with PEA, cardiac massage to ECMO then pulmonary thrombectomy	N/A		None	No	N/A	N/A
²³⁷ Weinberg 2011	Case report	C/S	PAH, cardiac failure	27 year old G4P3 at 31 weeks with chronic pulmonary thromboembolic disease with RV dysfunction, post C/S ECMO cannulated catheter thrombolysis and suction catheter embolectomy	VA	4	Renal replacement therapy, trach	No	Preterm delivery at 31 weeks, intubated, NICU	No
²³⁸ Welch 2010	Case report	C/S	ARDS	34 year old G2P1 at 21 weeks with ARDS due to H1N1	VV	19	VAP, trach, severe weakness	No	Preterm delivery at 35 weeks	No
²³⁹ Wertasc hnigg 2017	Case series	C/S	Cardiac arrest	Patient with prolonged AVNRT emergency C/S cardiac arrest cannulated immediately postpartum	VA	10	Brain bleed	Yes	N/A	N/A

²³⁹ Wertasc hnigg 2017	Case series	C/S	PE, cardiac arrest	Patient with massive PE with cardiac arrest s/p C/S cannulated immediately postpartum	VA		Brain bleed	Yes	N/A	N/A
²³⁹ Wertasc hnigg 2017	Case series	VD	ARDS	Patient at 24 weeks with H1N1 ARDS	VV		Preterm labor at 26 weeks, NICU	No	Preterm labor at 26 weeks, NICU	No
²⁴⁰ Weyrich 2016	Case report	C/S	PPH, ARDS, cardiac arrest	36 year old G6P5 at 38 weeks with uterine rupture, PPH, ARDS c/b bradycardia s/p CPR refractory hypoxemia cannulated on PPD# 10	VV	50	Bladder bleeding s/p coagulation, bacterial contamination of circuit, trach	No	N/A	No
²⁴¹ Williams 2008	Retrospective review	N/A	ARDS, cardiac failure, HELLP	17 patients included for various indications including infectious (9), cardiac (4), HELLP (3)	N/A			4/17	3 patients on ECLS with pre-viable fetus and all died, 1 before ECLS, 1 maternal death, 1 IUFD during ECLS	3/17
²⁴² Wise 2016	Case report	VD	AFE, cardiac arrest	34 year old G1P0 at 39 and 4/7 weeks with AFE, hemodynamic collapse with RDS, VAVD	VV then VA	3	Need for dialysis during hospitalization, ischemic bullae on lower extremities secondary to reperfusion injury and multiple sacral wounds; No longer required CRRT at 3 months follow up	No	None	No
²⁴³ Yang 2007	Case report	N/A	PPCM	18 year old at 40 weeks with desaturation during C/S, HTN, severe pulmonary edema, EF 18%,	VA	0.85714	Vaginal bleeding	No	N/A	N/A
²⁴⁴ Yang 2014	Case report	N/A	PE, cardiac arrest	30 year old G4P1 at 36 and 5/7 weeks with massive PE c/b PEA given tPA underwent thrombectomy under ECMO	VA	7	DIC, transfusions, intracranial hemorrhage	Yes	N/A	No

²⁴⁵ Yeh 2013	Case report	VD	Heart disease, cardiac failure	25 year old on PPD# 7 with hypoxia found to have giant PDA and Eisenmenger	N/A	30	Multiorgan failure, pulmonary HTN	Yes	N/A	N/A
²⁴⁶ Young 2016	Case report	C/S	PE, cardiac arrest	39 year old on PPD# 0 from cesarean delivery with cardiac arrest s/p CPR found to have massive PE, RV dysfunction s/p ECMO then mechanical thrombectomy	N/A	1	Abdominal compartment syndrome, uterine bleeding, laparotomy, hospitalized for 6 weeks, d/c to PT	No	N/A	N/A
²⁴⁷ Zhang 2018	Case series	C/S	PAH, heart failure	22 year old G2P0 at 37 weeks with PAH cannulated postpartum	VA		Pulmonary hypertension crisis, HF	Yes	Neonatal distress, NICU	No
²⁴⁷ Zhang 2018	Case series	C/S	PAH, heart failure	25 year old G5P1 at 32 weeks with PAH cannulated postpartum	VA		Pulmonary hypertension crisis, HF	Yes	Preterm delivery at 32 weeks, NICU admission	No
²⁴⁸ Zhang 2018	Case series	C/S	PAH	Patient on PPD# 0 with RV failure after delivery/oxytocin requiring ECMO	VA	3		Yes	Preterm delivery	No
²⁴⁸ Zhang 2018	Case series	C/S	PAH	Patient on PPD# 0 with RV failure after delivery/oxytocin requiring ECMO	VA	5		Yes	Neonatal distress (NICU admission)	No
²⁴⁹ Zingel 2012	Case report	C/S	PPCM	30 year old G1P1 with PPCM 17 days postpartum, medically treated then IABP/ECMO	N/A		None, total ICU course was 14 days	No	N/A	N/A
²⁵⁰ Zykova 2010	Retrospective review	N/A	ARDS	25 year old with H1N1 flu while pregnant	N/A			No	N/A	N/A

ECLS = extracorporeal life support; VD = vaginal delivery; VAVD = vacuum-assisted vaginal delivery; C/S = cesarean delivery, D&C = dilation and curettage; VV = venovenous; VA = venoarterial; NICU = neonatal intensive care unit; ARDS = acute respiratory distress syndrome; PAH = pulmonary arterial hypertension; PEA = pulseless electrical activity; CPR = cardiopulmonary resuscitation; PNA = pneumonia; TRALI = transfusion related acute lung injury; ECPR = extracorporeal cardiopulmonary resuscitation; PE = pulmonary embolism; AFE = amniotic fluid embolism; DIC = disseminated intravascular coagulation; BKA = below the knee amputation; DVT = deep vein thrombosis; GA = gestational age; PPH = postpartum hemorrhage; tPA = tissue plasminogen activator; D&E = dilation and evacuation; IUFD = intrauterine fetal death; ILD = interstitial lung disease; IOL = induction of labor; RV = right ventricle; PPCM = peripartum cardiomyopathy; VT = ventricular tachycardia; LV = left ventricle; EF = ejection fraction; GAS = group A streptococcus; SAB = spontaneous abortion; MS = mitral stenosis; TAB = therapeutic abortion; TTP = thrombotic thrombocytopenic purpura; HELLP = hemolysis, elevated liver enzymes, low platelets; ECCO₂ removal = extracorporeal carbon dioxide removal; HIT = heparin induced thrombocytopenia; IVIG = intravenous immunoglobulin; PA = pulmonary artery; PTE = pulmonary thrombectomy; ED = emergency department; TTE = transthoracic echocardiogram; IUGR = intrauterine growth restriction; AML = acute myeloid leukemia; iLA = interventional lung assist; LAM = lymphangioliomyomatosis; DAH = diffuse alveolar hemorrhage; RDS = respiratory distress syndrome; d-TGA = dextro-transposition of the great arteries; MV = mitral valve; HF = heart failure; OR = operating room; HD = hemodialysis; BiVAD = biventricular assist device; IABP = intraaortic balloon pump; ACS = acute coronary syndrome; LAD = left anterior descending coronary artery; POD = post-operative day; CABG = coronary arterial bypass graft; SCAD = spontaneous coronary artery dissection; CPB = cardiopulmonary bypass; SVT = supraventricular tachycardia; AKI = acute kidney injury; VAP = ventilator associated pneumonia; NSCLC = non-small cell lung cancer; LVAD = left ventricular assist device; PTX = pneumothorax; IVH =

intraventricular hemorrhage; PEG = percutaneous endoscopic gastrostomy; PPD = postpartum day; POC = products of conception; POD = postoperative day; ICU = intensive care unit; UAE = uterine artery embolization; TAE = transcatheter arterial embolization; Vfib = ventricular fibrillation; SOB = shortness of breath; BiV = biventricular; SVG = saphenous vein graft; UA = umbilical artery; MI = myocardial infarction; pheo = pheochromocytoma; CHF = congestive heart failure; CHD = congenital heart disease; VSD = ventricular septal defect; MARS = molecular adsorbent recirculating system; TAH = total artificial heart; OHT = orthotopic heart transplantation; SVC = superior vena cava; ALL = acute lymphoblastic leukemia; CVVH = continuous veno-venous hemofiltration; NO = nitric oxide; ICD = implantable cardioverter defibrillator; LOS = length of stay; GI = gastrointestinal; BAL = bronchoalveolar lavage; VF.= ventricular fibrillation; PRIS = propofol infusion syndrome; BPD = bronchopulmonary dysplasia; NAS = neonatal abstinence syndrome; AVCO₂ = extracorporeal arteriovenous carbon dioxide removal; MRSA = methicillin resistant staph aureus; WPW = Wolff-Parkinson-White syndrome; CM = cardiomyopathy; RFA = radiofrequency ablation; SROM = spontaneous rupture of membranes; CF = cystic fibrosis; STEMI = ST elevation myocardial infarction; TEE = transesophageal echocardiogram; AKA = above knee amputation; CRRT = continuous renal replacement therapy; HTN = hypertension; PDA = patent ductus arteriosus

Table S2. Cases of deliveries on ECMO (n = 35).

Study (Author, Year)	Delivery Type	Case details	ECLS Type	ECLS Duration (Days)	Maternal Complications	Maternal Mortality	Cause of Maternal Death	Fetal Complications	Fetal Mortality	Anticoagulation
Agerstrand 2016³⁶	C/S	Patient at 34.9 weeks with PAH requiring VV support then septic shock requiring VA, on ECMO for 3 days prior to delivery	VV then VA	24	DIC, abdominal compartment syndrome, VV 12d then VA for 12d	No	N/A	N/A	Yes	N/A
Agerstrand 2016³⁶	C/S	Patient at 26.4 weeks with H1N1 ARDS	VV		ARDS, renal failure, septic shock, preeclampsia, DIC, multisite bleeding	No	N/A		N/A	N/A
Alyamani 2018³⁸	C/S	38 year old G9P8 at 30.4 weeks with sarcoidosis with ARDS, alveolar hemorrhage	VV	14	Profuse bleeding after bronchoscopy, DVT after decannulation	No	N/A	Preterm delivery at 31 weeks, NICU	No	Anticoagulated with institutional goal PTT 45-55
Bautista 2018⁴⁵	C/S	18 year old at 24 weeks with PAH due to chronic venoocclusive disease	VV	10	Worsening after VV ECMO decannulation, lung transplant complicated by rejection, hemodynamic and respiratory failure	Yes	Died 1 day after decannulation of cardiopulmonary failure	IUFD at 24 hours	Yes	N/A
Biderman 2017⁵⁰	VD	30 year old at 20 weeks with ARDS, infectious pneumonia with h. influenza and septic shock	VA	3	Tracheotomy	No	N/A	Died 3 days into ECLS	Yes	Heparin started at time of cannulation - 5000 IU bolus then gtt titrated to patient condition
Biderman 2017⁵⁰	VD	37 year old at 13 weeks with ARDS due to H1N1	VA then VV	16	Disseminated intravascular coagulation (DIC), tracheotomy; VA 7 days then VV for 9 days	Yes	Sepsis, died after decannulation	SAB	Yes	Heparin started at time of cannulation - 5000 IU bolus then gtt titrated to patient condition
Bowkalow 2011⁵³	VD	24 year old G4P2 at 20.9 weeks with H1N1 ARDS	N/A	28	Died	Yes	Multiorgan failure	SAB at 21 weeks	Yes	N/A
Bruch 2013⁵⁴	CD	31 year old G1P0 at 19 weeks with PE and cardiac arrest requiring CPR, ECLS and thrombectomy, stillbirth at 19 weeks requiring D&C	VA	5	Bleeding requiring transfusions	No	N/A	SAB on ECMO	Yes	N/A

Chao 2016 ⁵⁸	VD	35 year old G1P0 at 16 weeks with viral PNA causing hypoxemic respiratory failure, ARDS	VV	9		No	N/A	SAB at 16 weeks	Yes	N/A
Coscia 2012 ⁶⁶	CD	31 year old at 24 weeks with recent M3 AML developed hypoxemic respiratory failure c/b ARDS, spontaneously delivered 48 hours into iLA	iLA (VV)	8	Died 53 days after admission from AML complications	No	N/A	Unclear outcome, spontaneous preterm delivery at 24 weeks, NICU admission	N/A	iLA, no anticoagulation because PTT was 2.3x normal and platelets 57K
Crawford 2015 ⁶⁸	C/S	37 year old G1P0 at 21 weeks with influenza A ARDS c/b HELLP with newly diagnosed LAM (lymphangiioleiomyomatosis) and diffuse alveolar hemorrhage (DAH)	VV	14	Had lung biopsy for LAM during ECMO run, was given endobronchial recombinant factor VII during run	No	N/A	Preterm delivery at 24 weeks, NICU, respiratory/nutritional support	No	N/A
DiLorenzo 2016 ⁷²	C/S	Patient at 33 weeks with mitral valve regurgitation due to prosthetic valve thrombosis with NYHA Class III HF planned c/s after VA ECMO and MV replacement, ECMO in OR immediately before c/s	VA	2	None	No	N/A	N/A	No	Heparin continued with PTT goal 50-60
Jandhyala 1994 ¹¹⁸	VD	20 year old G3P1 at 30 weeks with ARDS secondary to e.coli urosepsis with refractory hypoxemia for ECCO ₂ removal	VV	1.833333	None	No	N/A	Preterm delivery at 30 weeks, NICU	No	Heparin with goal ACT 180-200 but reduced to 150 for delivery and first 6 hours after
Ju 2018 ¹²²	C/S	36 year old G2P1 at 21 weeks with twin pregnancy complicated by chorioamnionitis, septic shock	VV	9	Fingertip amputation due to ischemia	No	N/A	Therapeutic abortion, twins	Yes	Anticoagulated with goal ACT 130-150
Kunstyr 2010 ¹³³	VD	26 year old at 24 weeks with H1N1 ARDS	VV	14	Hemorrhagic bronchitis, cephalic vein thrombosis, pseudomonas infection	No	N/A	Preterm delivery at 24 weeks, NICU, respiratory support	No	On heparin target ACT 160-180, PTT 50-60, stopped infusion for delivery and resumed 3 hours later
Lee 1997 ¹³⁶	VD	26 year old at 17 weeks with varicella PNA ARDS	VA to VV	57	Cannula dislodgment, bilateral tension hemopneumothoraces, bronchopleural fistulas, multiple re-explorations for bleeding, right heart	Yes	Multiple organ system dysfunction	SAB at 21 weeks	Yes	N/A

					failure, hepatic abscesses					
Lysenko 2014 ¹⁴⁶	C/S	24 year old G1P0 at 39.4 weeks with H1N1 ARDS, cesarean delivery at 30 weeks 3 days	VV	17	None	No	N/A	Preterm delivery at 30 week, intubated, NICU admission	No	Discontinued heparin 5 hours before delivery and resumed 14 hours after delivery under GA - no bleeding or thrombotic complications
Meng 2017 ²³	C/S	Patient at 35 weeks with PAH due to CHD/Eisenmenger, cannulated 2 days before delivery	VV then VA	21	Discharged home on PPD24 found dead at home on PPD89, VV 15 days then VA 6 days	No	Postpartum day 89, unwitnessed cardiac arrest	Preterm delivery at 35 weeks	No	N/A
Mikami 2018 ¹⁵⁴	C/S	38 year old G3P2 at 35. weeks with PPCM EF10%, had IABP and ECMO prior to cesarean	VA	8	Uterine bleeding s/p Bakri, transcatheter arterial embolization, hysterectomy	No	N/A	Preterm delivery at 35 weeks, neonatal asphyxia, therapeutic hypothermia, NICU	No	Unfractionated heparin to maintain ACT 180-200
Morsolini 2017 ¹⁵⁶	C/S	Patient at 31 weeks with PAH	VA	1.083333	SVC and PA thrombosis	No	N/A	None	No	Low anticoagulation used with goal PTT 40-50, all had heparin gtt and it was held during c/s
Morsolini 2017 ¹⁵⁶	C/S	Patient at 31 weeks with H1N1 ARDS	VV	31	Gastrointestinal bleeding	No	N/A	IVH, discharged alive	No	Low anticoagulation used with goal PTT 40-50, all had heparin gtt and it was held during c/s
Morsolini 2017 ¹⁵⁶	C/S	Patient at 31 weeks with mitral prothesis thrombosis complicated by heart failure	VA	1.5	PNA	No	N/A	None	No	Low anticoagulation used with goal PTT 40-50, all had heparin gtt and it was held during c/s
Morsolini 2017 ¹⁵⁶	C/S	Patient at 31 weeks with PAH	VA	0.916667	Uterine bleeding	No	N/A	None	No	Low anticoagulation used with goal PTT 40-50, all had heparin gtt and it was held during c/s
Panarello 2010 ¹⁶⁵	C/S	H1N1 ARDS			None reported					N/A

Panarello 2011 ¹⁶⁶	C/S	38 year old at 25 weeks with H1N1 ARDS	VV	35	Cesarean delivery at 30 weeks to improve pulmonary mechanics, active bleeding ulcer	No	N/A	Preterm delivery at 30 weeks, intracranial hemorrhage, intubation, NICU	No	On heparin for beginning of run, held for 2 hours prior to C/S then resumed 2 hours post-op with goal PTT 40-50
Park 2014 ¹⁶⁷	C/S	34 year old G2P1 at 37 weeks with PPCM EF 39% and worsening heart failure, planned VA ECMO prior to cesarean	VA	6	None	No	N/A	NICU admission, respiratory support	No	Held of anticoagulation until 3 days postpartum, then started nafamostat mesilate
Radsel 2018 ¹⁸⁶	VD	29 year old G1P0 at 23 weeks with H1N1 ARDS	VV	10	Decannulated on day 5 then recannulated, preterm labor, critical illness polyneuropathy, tracheostomy, discharged to rehabilitation	No	N/A	Preterm delivery at 25 weeks, NICU, intubated, BPD, NAS from maternal sedation	No	Had UFH goal PTT 40-50 then anti-Xa 0.2-0.3IU/mL prior to delivery, got protamine after delivery then lovenox postpartum
Satoh 2002 ²⁰¹	C/S	33 year old G1P0 at 18 weeks with PAH with mean PA pressure in 70s and worsening of symptoms; termination of pregnancy at 18 weeks on ECMO	VA	19	Coagulation of artificial lung requiring changing	Yes	Right heart failure	Therapeutic abortion	Yes	Heparin bonding circuit, heparin bonding cannulae, ACT 140-150 and mention of use of anticoagulant but not explicitly stated
Shamsah 2017 ²¹⁰	VD	25 year old G2P1 at 26 weeks with PAH, heart failure s/p arrest during labor, delivered amidst CPR and ECMO cannulation	VA	14	Prepared for heart/lung transplant but abruptly decompensated and died	Yes	Worsening PAH after ECLS	Preterm delivery at 26 weeks, NICU	N/A	N/A
Sharma 2015 ⁸	VD	Patient at 34 weeks with cardiogenic shock, likely viral etiology	VA	6	STEMI, vaginal bleeding, clot in circuit	No	N/A	Preterm delivery at 34 weeks, stillborn	Yes	Heparin with ACT 160-180, PTT 50-80, TEG 2.5-3x normal
Sim 2012 ²¹³	C/S	28 year old at 26 weeks with refractory SVT with cardiogenic shock crashed to ECMO, had IUFD, had RFA, later cesarean delivery	VA	7	None reported	No	N/A	SAB at 26 weeks	Yes	N/A

Takacs 2018 ²²¹	VAVD	21 year old G3P2 at 24 weeks with cardiac arrest with CPR, rupture of membranes during resuscitation, pulmonary contusions and ARDS, received enoxaparin, developed IUFD and DIC	VA	7	SAB during collapse, DIC while on ECLS, possibly due to IUFD so underwent IOL, VAVD, retained POC, subsequent D&C on ECMO	No	N/A	IUFD prior to ECLS	N/A	N/A
Vitolo 2017 ²³³	C/S	31 year old at 32 weeks with PAH, scheduled cesarean delivery with planned pre-incision ECMO	VA	1	Urgent re-laparotomy for bleeding on POD3, thought not to be related to ECMO	No	N/A	Preterm delivery at 32 weeks, NICU admission	No	N/A
Wang 2015 ²³⁵	VD	29 year old at 27 year weeks with H7N9 influenza ARDS	VV then VA	19	Heart failure, sepsis due to acinetobacter, PE; VV 4 days VA 15 days	Yes	Pulmonary embolism 3 days after decannulation	SAB delivered 4 days after loss of fetal heart tones	Yes	N/A
Wertaschnigg 2017 ²³⁹	VD	Patient at 24 weeks with H1N1 ARDS	VV		None reported	No	N/A	Preterm labor at 26 weeks, NICU	No	N/A

ECLS = extracorporeal life support; VD = vaginal delivery, C/S = cesarean delivery, VV = venovenous, VA = venoarterial, iLA = interventional lung assist, SAB = spontaneous abortion, IUFD = intrauterine fetal death, NICU = neonatal intensive care unit, IVH = intraventricular hemorrhage; gtt = infusion; PTT = partial thromboplastin time; DIC = disseminated intravascular coagulation; ARDS = acute respiratory distress syndrome; DVT = deep vein thrombosis; PAH = pulmonary arterial hypertension; LAM = lymphangioleiomyomatosis; iLA = interventional lung assist; ECCO₂ removal = extracorporeal carbon dioxide removal; HELLP = hemolysis, elevated liver enzymes, low platelet syndrome; MV = mitral valve; ACT = activated clotting time; PNA = pneumonia; CHD = congenital heart disease; IABP = intra-aortic balloon pump; PPCM = peripartum cardiomyopathy; SVC = superior vena cava; PA = pulmonary artery; EF = ejection fraction; CPR = cardiopulmonary resuscitation; STEMI = ST elevation myocardial infarction; TEG = thromboelastography; SVT = supraventricular tachycardia; RFA = radiofrequency ablation; IOL = induction of labor; VAVD = vacuum assisted vaginal delivery; POC = products of conception; D&C = dilation and curettage

Table S3. Cases that included cardiopulmonary bypass (CPB) (n = 11).

Study (Author, Year)	Stage of Pregnancy	Postpartum Day	Delivery	Disease Process/Indication	ECLS Type	ECLS Duration (Days)	Maternal Complications	Maternal Mortality	Fetal Complications	Fetal Mortality
Arlt 2009 ⁴⁰	Immediately postpartum	0.166666667	C/S	27 year old with massive PE complicated by PEA given tPA, ECMO transported with hand-held system, underwent emergent hysterectomy and pulmonary thrombectomy under ECMO	VA	4	Vaginal and endotracheal bleeding after thrombolysis, emergency hysterectomy	No	N/A	No
Bruch 2013 ⁵⁴	Antepartum	N/A	VD	31 year old G1P0 at 19 weeks with PE and cardiac arrest requiring CPR, ECLS and thrombectomy, stillbirth at 19 weeks requiring D&C	VA	5	Delivered on ECMO, bleeding requiring transfusions	No	SAB on ECMO	Yes
Chuang 2015 ⁶³	Postpartum	2	C/S	29 year old G1P1 with PE s/p cardiac arrest and CPR underwent PTE 2 days after admission	VA	2	Burn injuries from resuscitation in ED, staph and influenza infections, discharged day 43	No	N/A	N/A
DiLorenzo 2016 ⁷²	Antepartum	N/A	C/S	Patient at 33 weeks with mitral valve regurgitation due to prosthetic valve thrombosis with NYHA Class III HF planned cesarean after VA ECMO and MV replacement, ECMO in OR immediately before delivery	VA	2	Delivered on ECMO	No	N/A	No
Evans 2014 ⁷⁶	Postpartum	14	Not noted	Patient with ACS diagnosed with SCAD to the LAD with EF 15-20% s/p CABG with failure to wean from CPB	VA	10	Rehab	No	None	N/A
Fabricius 2001 ⁷⁸	Immediately postpartum	0	C/S	32 year old G1P0 at 39 weeks had cesarean delivery for fetal tachycardia, found to have type A aortic dissection with cardiogenic shock	VA	4	None	No	None	No
Fayad 2007 ⁸¹	Postpartum	<7 days	C/S	31 year old delivered at 30 weeks with post-rheumatic mitral stenosis, dilated RV had CPB then planned transition to ECMO	VA	9	Ventilator associated pneumonia with pseudomonas then sepsis, pre-operative renal failure	Yes	Preterm delivery at 30 weeks, NICU respiratory support	N/A

Halldorsdottir 2016 ⁹⁸	Immediately postpartum	0	C/S	29 year old G3P1 at 37 weeks with cardiogenic shock after cesarean delivery due to MV prosthesis thrombosis with severe hypoxemia, cannulated 2 hours postpartum	VA	3	Weaned from CPB after MV replacement, on ECMO before CPB	No	None	No
Hansen 2012 ¹⁰⁰	Postpartum	6	D&C	38 year old with septic shock for retained products of conception, underwent D&C before IABP and then VA ECMO, found to have papillary muscle rupture, had 2 days ECMO before MV replacement	VA	2	Severe aortic insufficiency, went back to OR on POD9	No	N/A	N/A
Knapp 2016 ¹²⁷	Postpartum	16	C/S	30 year old with SCAD s/p multiple stents s/p CABG with saphenous vein grafts to LAD and circumflex	VA	4	Post-CABG biventricular dysfunction EF 25%	No	N/A	N/A
Wei 2011 ²³⁶	Postpartum	2	C/S	36 year old G1P1 delivered at 37 weeks with PE and cardiac arrest, cardiac massage to ECMO then pulmonary thrombectomy	N/A	<1	None	No	N/A	N/A

ECLS = extracorporeal life support; VD = vaginal delivery, C/S = cesarean delivery, D&C = dilation and curettage, VV = venovenous, VA = venoarterial, SAB = spontaneous abortion, NICU = neonatal intensive care unit; PE = pulmonary embolism; PEA = pulseless electrical activity; tPA = tissue plasminogen activator; CPR = cardiopulmonary resuscitation; PTE = pulmonary thrombectomy; ED = emergency department; OR = operating room; ACS = acute coronary syndrome; LAD = left anterior descending coronary artery; POD = post-operative day; CABG = coronary arterial bypass graft; MV = mitral valve; SCAD = spontaneous coronary artery dissection